BrienHoldenVisionInstitute

GLAUCOMA AND RETINAL DISEASE

THINK

While you do ophthalmoscopy on a woman's right eye, you see some dark pigment on the fundus. How will you know if this is normal?

WHAT YOU WILL LEARN

When you have worked through this unit you should know how to:

- List and describe the main types of retinal disease
- Describe when to refer retinal conditions to an ophthalmologist or medical practitioner.

Copyright © 2009

OPEN ANGLE GLAUCOMA

WHAT IS IT?	• There are two main types of glaucoma – angle closure glaucoma and open angle glaucoma • In angle closure glaucoma, there is a rapid or sudden increase in pressure inside the eye, because the iris is pushed up against the angle of the eye where the aqueous is drained (the anterior chamber angle is blocked or 'closed') • In open angle glaucoma, there is a gradual increase in pressure inside the eye – even though the anterior chamber angle is open • The increase in pressure inside the eye damages the retina and the optic nerve • This can lead to serious loss of vision and even blindness if it is not treated early • Open angle glaucoma is the most common type of glaucoma, and is also sometimes called 'chronic glaucoma' • It is quite a dangerous condition, since it progresses gradually and therefore often goes unnoticed for years • Open angle glaucoma usually affects both eyes.
CAUSES	• Aqueous in the anterior chamber normally drains out of the anterior chamber angle of the eye (where the iris and cornea meet) • In open angle glaucoma, there is a gradual blockage of aqueous outflow, or an overproduction of aqueous in the eye – causing a gradual increase in pressure inside the eye • We do not yet fully understand why this occurs • If the pressure in the eye (intra-ocular pressure) gets too high, it causes damage to the optic nerve – which can lead to blindness.
RISK FACTORS	• Age – open angle glaucoma typically occurs in people over 50 years of age • Family history of glaucoma • Medical conditions – people with diabetes or high blood pressure have a greater risk of getting glaucoma • High myopia (near sightedness) • Medicines, especially steroid use, increase the risk of developing open angle glaucoma.
SYMPTOMS	• In its early stages, open angle glaucoma usually has no symptoms • It is painless and happens very slowly, so initially people are unaware that they have this problem with their eyes • Most people do not notice problems until quite a bit of visual loss has occurred – this makes it quite a dangerous condition • The outer (peripheral) field of vision is loss first • In later stages of glaucoma, people might complain of bumping into things, or that they cannot see in things in the periphery of their visual fields • Central vision is usually not lost until very late in the disease.

Copyright © 2009

SIGNS	• Cup to disc ratio (C:D ratio) of 0.5 or greater, or a difference of 0.2 or greater in C:D ratio between the two eyes • High pressures (greater than 20 mm Hg in either eye, or a difference of 2 mm Hg or greater between the two eyes) • Restricted confrontation fields • Optic nerve cupping (indentation of the optic disc) • Pale coloured optic nerve • Retinal haemorrhages in and around the optic disc (splinter or flame shaped).
WHAT DOES IT LOOK LIKE?	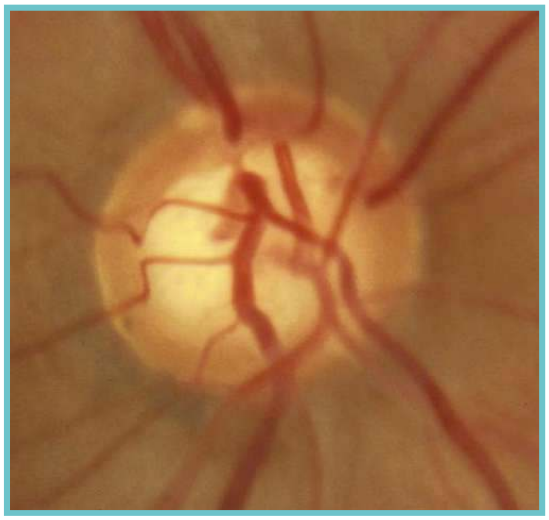 ***Figure 13-1: C:D ratio > 0.6 because of glaucoma [photo courtesy of Richard Bourne: ICEH]*** ***Figure 13-2: Splinter haemorrhage in the retina as a result of glaucoma [photo courtesy of Richard Bourne: ICEH]***

Copyright © 2009

TREATMENT PLAN	• Open angle glaucoma has no symptoms in its early stages • Once the damage is done to the optic nerve, you cannot restore vision • There is no cure for glaucoma, but it can be controlled by lowering the pressure inside the eye – to prevent or delay further damage to the optic nerve • The intra-ocular pressure is usually lowered with the use of eye drops, and/or other medications, surgery or laser treatments • Chronic (open angle) glaucoma can only be detected by regular eye examinations, which include the measurement of intra-ocular pressure (tonometry) and examination of the optic disc and retina (ophthalmoscopy) • Vision loss and blindness can be prevented by early diagnosis and treatment of glaucoma.

REFERRAL CRITERIA	• Refer anyone with:
	  ○ C:D ratio of 0.5 or greater, or a difference of 0.2 or greater in C:D ratio between the two eyes
	  ○ High intra-ocular pressures (e.g. 20 mm Hg or above)
	  ○ Restricted visual fields (confrontation test)
	  ○ Anyone you suspect may have glaucoma due to risk factors such as a family history or diabetes.

- **If untreated, glaucoma can cause blindness**
- **It is important to refer anyone whom you think might have glaucoma.**

Copyright © 2009

AGE RELATED MACULAR DEGENERATION (ARMD)

WHAT IS IT?	• Macular degeneration is a disease of the macula – the part of the eye responsible for fine central vision • The disease is associated with ageing, and commonly occurs in people over the age of 65 • Macular degeneration causes a destruction of the person's central vision • This loss of central vision causes the person to have difficulty performing daily tasks like reading, driving and recognising faces.

CAUSES	• Age-related macular degeneration (ARMD) occurs in two forms – wet ARMD and dry ARMD
	• Dry ARMD:
	  ○ Occurs when light sensitive cells in the retina slowly break down (degenerate)
	  ○ This causes a build-up of waste products in the macula
	  ○ Central vision gradually becomes blurry
	  ○ Usually both eyes are affected, but vision loss could be more significant in one eye
	  ○ Most people with ARMD have this type
	  ○ A person with dry ARMD can eventually also develop wet ARMD
	• Wet ARMD:
	  ○ Occurs when new, abnormal blood vessels behind the retina start to grow under the macula
	  ○ These blood vessels are weak and often leak blood and fluid
	  ○ This can cause very sudden damage to the macula, with rapid loss of central vision
	  ○ When a person has wet ARMD, straight lines (such as an Amsler grid) will look wavy.

RISK FACTORS	• Age is the greatest risk factor (over 60 years old) • Family history of ARMD • Smoking cigarettes • Obesity • Gender (women are at greater risk than men of developing ARMD).

SYMPTOMS	• Both wet and dry ARMD do not cause any pain
	• Dry ARMD symptoms:
	  ○ The ARMD might advance very slowly, and the person might notice very little change in their vision
	  ○ The person may notice a blurred spot in the centre of their vision, which sometimes goes away in bright light
	  ○ They may require more light for tasks such as reading
	  ○ As the ARMD increases, the person may see a growing blind spot in the centre of their field of vision
	  ○ The person is not able to see much detail, such as faces or words in a book
	• Wet ARMD symptoms:
	  ○ Straight lines look wavy or crooked – because fluids from the leaking blood vessels lift the macula and distort the central vision
	  ○ A central blind spot and a loss of central vision could occur.

Copyright © 2009

WHAT DOES IT LOOK LIKE?	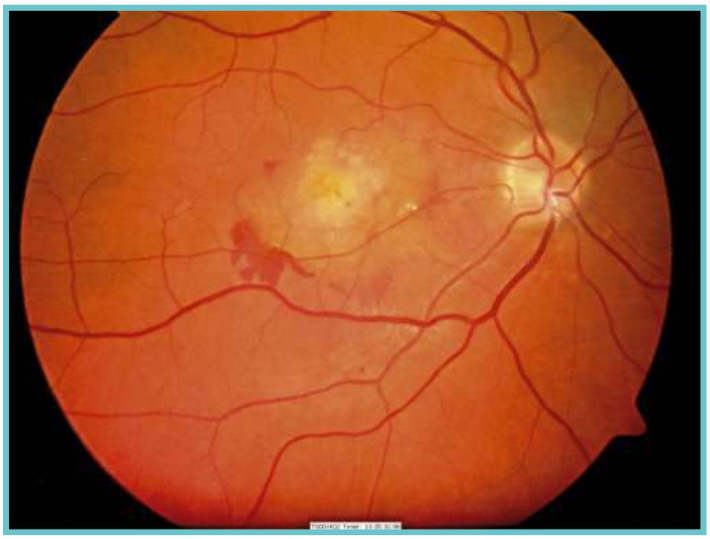 ***Figure 13-3: Macular degeneration – note the white patch and the haemorrhage in the macular area*** ***[photo courtesy of David Yorston: ICEH]***

SIGNS	• Distortion of straight lines (noted on Amsler Grid)
	• One of the most early common signs of dry ARMD is drusen at the macula
	  ○ Drusen are yellow deposits under the retina
	  ○ In the early stages, there are usually small or medium-sized drusen, which do not always cause vision loss
	  ○ The drusen increase in size and number as the ARMD develops, gradually causing a loss of central vision
	• Other signs of ARMD include;
	  ○ Green/Red spots at the macula
	  ○ Macula haemorrhages (blood on the retina)
	  ○ Pigment at the macula (brown/black spots).

WHAT SHOULD I DO?	• Check visual acuity (distance and near) • Examine the fundus (ophthalmoscopy) • Ask the person to look at an Amsler grid – and to let you know if any of the lines appear wavy/distorted/missing.
TREATMENT	• Once dry ARMD is well advanced, no form of treatment can prevent vision loss • A diet high in anti-oxidants, some vitamins and minerals might delay the advancement of the condition and the loss of central vision • Wet ARMD can be treated with laser surgery, special light therapy or injections into the eye. This is an immediate referral.
REFERRAL CRITERIA	Refer the person to an ophthalmologist if: • If a person has sudden central vision loss or distortion of the Amsler grid, you should refer them to an ophthalmologist immediately. • They have an abnormal looking macula • They complain of loss of central vision, especially if they are over 60 or have any of the risk factors for ARMD • They notice any distortion or missing lines on the Amsler grid.

Copyright © 2009

RETINAL VEIN OCCLUSION

WHAT IS IT?	• A blockage or blood clot in one of the blood vessels which drain blood out of the retina • When the vein blocks, the blood in it stops flowing and it cannot drain the blood out of the retina • Some blood and other fluids leak out of the blocked vein into the retina – affecting the person's vision • If the obstruction or occlusion occurs in the central retinal vein (where it enters the retina at the optic disc), the blood flow of the entire retina is affected • If the obstruction occurs in a branch of the retinal vein, it will be less severe and the person might only notice it if their central vision is affected • Retinal vein occlusion occurs unilaterally (in one eye only) • It is a fairly common cause of blindness or painless vision loss – especially in older people • It is more common in the elderly population, who also have a history of diabetes and/or hypertension.
CAUSES	• Retinal vein occlusions can be caused by an abnormal blood flow, blockage of the blood vessels and/or weakening of the blood vessels • Usually associated with systemic disease (e.g. diabetes and hypertension).
RISK FACTORS	• Age (more common in people over 50 years old) • High blood pressure • Obesity • Raised blood cholesterol levels • Diabetes • Glaucoma • Smoking.
SYMPTOMS	• Painless • May have a sudden loss of vision • Could be a total loss of vision in one eye (central retinal vein occlusion), or part of the visual field may be lost (branch retinal vein occlusion) • Visual acuity my range from 6/6 to finger counting (depending on whether or not the macula is involved and central vision is affected) • The person may complain of have flashes and floaters in their vision.
WHAT SHOULD I DO?	• Check visual acuity • Examine the fundus (ophthalmoscopy).
SIGNS	• May have reduced vision or loss of vision • May have a visual field defect • Blood on the retina (in all four quadrants of the retina or just half) • The haemorrhaging in the retina may be so severe • Swelling of the optic disc • May have cotton wool spots on retina • May have an abnormal pupil reaction to light in the affected eye • May see swelling of the macula and distortion on the Amsler Grid • A few months or week later, new blood vessels may develop in the eye.

Copyright © 2009

WHAT DOES IT LOOK LIKE?

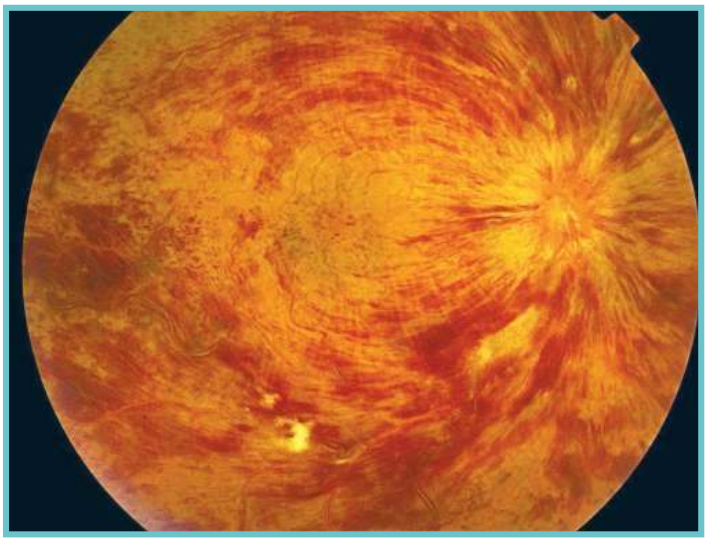

Figure 13-4: Central retinal vein occlusion; much swelling and blood on the retina
[photo courtesy of ICEH]

Figure 13-5: A much smaller (branch) retinal vein occlusion
[photo courtesy of ICEH]

Copyright © 2009

TREATMENT	• There is no known effective treatment available to prevent or treat retinal vein occlusion
	• Management is often focussed on treating the systemic disease which caused the problem
	• The person should be monitored closely for a few months, to look for signs of other complications
	• Common complications that can develop include:
	  ○ The formation of new blood vessels in the eye (could be in the iris)
	  ○ Glaucoma
	• Treatment with certain medications to reduce blood clotting can be successful
	• Some ophthalmologists also treat the eye with lasers – this can help to prevent the formation of new blood vessels in the eye
	• Even without treatment, about two thirds of people will recover at least part of their vision within a year or so
	• Addressing the risk factors (such as diabetes, smoking and obesity) can reduce the high risk of recurrence of retinal vein occlusion.

REFERRAL CRITERIA	Refer to an ophthalmologist anyone with: • Blood on the retina • Sudden, unilateral loss of vision.

Copyright © 2009

RETINISTIS PIGMENTOSA

WHAT IS IT?	• Retinitis pigmentosa (RP) is a hereditary eye disease – which means it occurs in people who have a family history of the condition • The retinal cells which are responsible for night vision (called the 'rods') are usually abnormal • This disrupts the normal function of the retina and affects vision • The first signs and symptoms can appear when the person is very young • Severe vision loss usually only develops in adulthood • As the disease develops and gets worse, side (peripheral) vision is lost • RP is a bilateral condition (it occurs in both eyes) • Often affects males more than females.
CAUSES	• RP is a hereditary condition (passed on from parent to children) – the main risk factor is a family history of the condition • It is uncommon (affecting only about 1 in 5000 people) • Usually, the light sensitive rod cells in the peripheral retina are lost first • As more of these rod cells degenerate or die, the person loses their peripheral vision • The person develops tunnel vision – they lose peripheral vision, but their central vision usually remains.
WHAT SHOULD I ASK?	• Is there any history of blindness in the family?
SYMPTOMS	• Symptoms usually develop some time after childhood (between the ages of 10 and 30 years old) • Difficulty seeing in the dark or in dimly lit areas • Light and glare sensitivity • Notice small flashes of light or visual aura in their peripheral vision • Loss of peripheral (side) vision and a narrowing of the visual field (tunnel vision) • Decreased visual acuity in later stages. .
WHAT SHOULD I DO?	• Measure visual acuity • Examine the fundus (ophthalmoscopy) • Examine the visual field if possible (confrontation fields are useful) • Do a colour vision test (if possible).
SIGNS	• Decreased visual acuity (especially later in the disease) • Loss of peripheral vision (tunnel vision) • Groups of small pigment clusters or dark lines on the peripheral retina • Pale appearance of the optic nerve • Loss of colour vision • Cataract is often associated with RP.

Copyright © 2009

TREATMENT	• Currently there is no standard treatment to cure or prevent the further development of retinitis pigmentosa • The use of low vision aids can help improve a person's quality of life • Many researchers around the world are working to find a solution to this condition • People who have this condition are often advised to seek genetic counselling before they have children – since it is passed on from generation to generation.
REFERRAL CRITERIA	• Anybody suspected of having retinitis pigmentosa should be referred to an ophthalmologist or medical practitioner • Anyone who shows the signs and/or symptoms of retinitis pigmentosa should be referred to an ophthalmologist • Because it is a hereditary condition, family members of a person with RP should also be examined and referred.

Copyright © 2009

SWELLING OF THE OPTIC NERVE

WHAT IS IT?	• Swelling of the optic nerve • Also called papilloedema • The edges of the disc are blurred and the swelling has filled the cup • Chronic swelling of the optic nerve can lead to optic nerve atrophy (death) and vision loss • The swelling is usually bilateral (affecting the optic discs of both eyes) • Can occur over a period of hours or weeks • Optic nerve swelling can be a sign of a life threatening condition (such as a brain tumour of infection) so early detection can save somebody's life • Fortunately it is quite a rare condition.
CAUSES	• Can be caused by increased pressure in the space between the skull and the brain (increased intracranial pressure) • Can be caused by problems like brain tumours, brain haemorrhage, head trauma or brain infections.
RISK FACTORS	• Diseases such as multiple sclerosis and meningitis • Obesity • Certain medications.

SYMPTOMS	• Person can be asymptomatic (i.e. they have no symptoms) – especially in the early stages
	• Papilloedema is sometimes only noted on routine ophthalmoscopy examination
	• As the swelling progresses, the person may develop symptoms such as:
	  ○ Headaches
	  ○ Nausea and vomiting
	  ○ Double vision
	  ○ Fluctuating vision loss
	  ○ Blurred vision
	• If the swelling develops and lasts for a long time, the person could ultimately have a total loss of vision.

WHAT DOES IT LOOK LIKE?	 ***Figure 13-6: Optic nerve swelling – note that you can't see the optic cup and the edges of the disc are blurry*** ***[photo courtesy of Jennifer Yip: ICEH]***

Copyright © 2009

	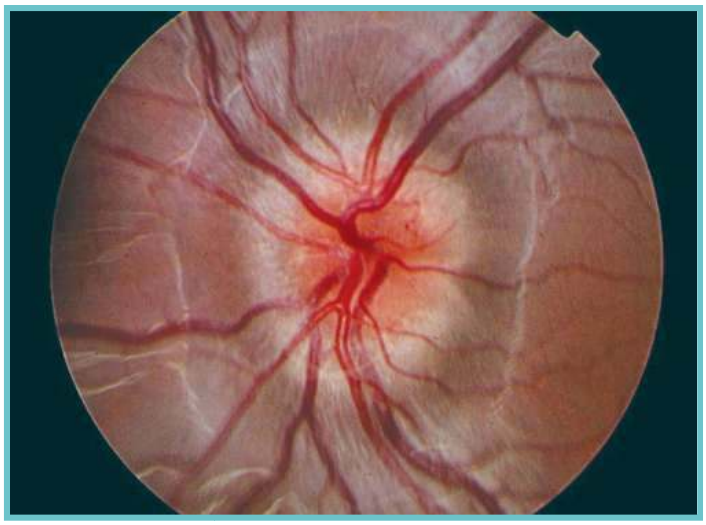 ***Figure 13-7: Swelling of the optic nerve (papilloedema) – note how the disc looks raised*** ***[photo courtesy of the ICEH]***
SIGNS	• The optic disc looks raised or elevated • Blurring of the optic disc margins (edges) • Filling of the optic disc cup • Engorgement or congestion of the retinal veins • Optic nerve could be pale or light pink / yellow • Small haemorrhages over or around the optic disc • Visual field loss (enlarged blind spot) • May have abnormal pupil reactions to light.
REFERRAL CRITERIA	• Any person who shows signs of papilloedema should immediately be referred to a medical practitioner! • The underlining condition (which causes the raised intracranial pressure) needs to be identified and treated • Unless the intracranial pressure is reduced, the optic nerve will be permanently damaged – which could result in serious vision loss.

- **Optic nerve swelling (papilloedema) can be a sign of a brain tumour which can be life threatening**
- **If you ever have doubt about something you see, it is always safer to refer to a medical practitioner for a second opinion.**

Copyright © 2009

HYPERTENSIVE RETINOPATHY

WHAT IS HYPERTENSION?

- Hypertension is high blood pressure – which means that a person's blood is pumping with more force than normal through their arteries
- This added stress can damage the arteries, which could lead to problems such as heart attack, kidney problems and stroke
- Blood pressure numbers are written with a top number (systolic) and a bottom number (diastolic)
- Normal blood pressure is around 120 / 80
- High blood pressure (hypertension) is classified as 140 / 90 and above
- Risk factors for hypertension include:
  - A family history of the condition
  - Obesity
  - A diet high in salt
  - Lack of exercise
  - Heavy drinking and smoking
- Hypertension can also cause problems in the blood vessels retina – called hypertensive retinopathy
- In most cases, hypertension may be unknown to the patient (it is usually asymptomatic) and the eye exam may be the first time their hypertension is discovered.

WHAT IS HYPERTENSIVE RETINOPATHY?	• Hypertensive retinopathy is a damage to the retina due to high blood pressure • Everybody who has hypertension can get hypertensive retinopathy • More common in middle-aged or older people.
CAUSES	• High blood pressure (hypertension).
WHAT DO YOU ASK?	• Do you (or does anybody in your family) have high blood pressure? • Are you taking medication for high blood pressure? • When was the last time you had your blood pressure checked? • Have you noticed any changes in your vision?
SYMPTOMS	• Person is usually asymptomatic • May have decreased vision.
SIGNS	• Occasionally reduced vision, but usually vision is normal • Can see a swollen optic nerve • Small retinal haemorrhages (bleeds) – especially flame shaped haemorrhages • White spots on the retina (cotton wool spots) • Arteries are narrower than usual (e.g. AV ratio 1:4) • Veins are tortuous (wriggly) • Arteries may compress veins where the veins and arteries cross.
REFERRAL CRITERIA	• Refer anyone with hypertensive retinopathy to a general practitioner for a blood pressure check.

EDUCATION FOR HYPERTENSION:

- **Stress the importance of controlling their high blood pressure**
- **With the proper medication, diet and exercise they can prevent further damage to the retina caused by high blood pressure.**

Copyright © 2009

SUMMARY – RETINAL DISEASE

GLAUCOMA

- Increased pressure inside the eye that damages the optic nerve
- Caused by a blockage of the drainage system of the eye
- Has two forms: Open Angle Glaucoma and Closed Angle Glaucoma
- In its early stages it has no symptoms and is painless
- Eventually, it can lead to peripheral vision loss and then to blindness
- Refer all people with a large C:D ratio, reduced field of vision or high intraocular pressures

AGE RELATED MACULA DEGENERATION (ARMD)

- Is a disease that affects the macula
- Usually associated with ageing (over 60)
- It destroys central vision
- It has two forms:
  - Dry ARMD: gradual, painless distortion of central vision
  - Wet ARMD: severe central visual loss due to leakage of blood vessels in the macula
- Refer anyone with distortion on Amsler grid or who has an abnormal macula.

RETINAL VEIN OCCLUSIONS

- Is a blockage of the central retinal vein or a branch of the retinal vein
- Causes a unilateral, painless loss of vision
- It varies in severity and symptoms
- Refer anyone with bleeding of the retina.

RETINITIS PIGMENTOSA

- A hereditary condition that can be passed on from generation to generation
- The typical sign is groups a small clusters of pigment on the peripheral retina
- Can cause loss of peripheral vision and night blindness
- Refer the person and their family to a medical practitioner if you suspect they have retinitis pigmentosa.

SWELLING OF THE OPTIC NERVE

- Also called papilloedema
- Caused by increased intracranial pressure
- Often asymptomatic, especially in early stages
- Later symptoms could include headaches, nausea and double vision
- The optic nerve appears raised, with blurry edges
- Refer anyone you suspect of having optic nerve swelling URGENTLY.

HYPERTENSIVE RETINOPATHY

- Damaged to the retina caused by high blood pressure
- It usually has no symptoms
- May see haemorrhages and cotton wool spots on the retina
- Refer anyone with hypertensive retinopathy to have their blood pressure checked.

Copyright © 2009

TEST YOURSELF QUESTIONS

1. **Name three signs of glaucoma in the eye:**

_____
_____
_____

2. **Name two eye conditions that can cause Amsler Grid distortion:**

_____
_____

3. **You see a person with swelling of the optic nerve. How urgent is the referral and why?**

_____
_____
_____

4. **Name three risk factors for age related macular degeneration (ARMD):**

_____
_____
_____

5. **Name two retinal conditions caused or made worse by high blood pressure or diabetes:**

_____
_____

6. **You refer a person because you noticed small clusters of pigment on the peripheral retina. Why should you refer the person's children also?**

_____
_____
_____

Copyright © 2009