DIFFERENTIATING PRIMARY OPEN ANGLE GLAUCOMA

AUTHORS

Eric Conley

Sarah MacIver: University of Waterloo

PEER REVIEWER

Angel Novel Simmons: University of Missouri-St. Louis

CHAPTER CONTENTS

INTRODUCTION 1
GROSS EXTERNAL EXAMINATION 2
UTILIZATION OF SLIT-LAMP BIOMICROSCOPY TO RULE OUT SECONDARY AND ANGLE CLOSURE GLAUCOMA . 2
ASSESSMENT OF THE CORNEA 3
ANTERIOR CHAMBER 6
IRIS 11
CRYSTALLINE LENS AND GLAUCOMA 14
SUMMARY 16

INTRODUCTION

Alteration to the physical structure of the anterior chamber angle can impact the regulation of intra-ocular pressure (IOP). It is important to rule out secondary causes and angle closure when investigating primary open angle glaucoma.

Conditions that can impact the outflow system and raise IOP include:

- Trauma
- Systemic or localized etiologies involving inflammation
- Intra-ocular abnormalities that liberate cells into aqueous
- Congenital structural anomalies of the angle
- Age-related structural morphologies

Since IOP is a significant risk factor in glaucoma development, a thorough examination to rule out these conditions is critical.

Elevated intraocular pressure can be caused by the unintended release of various cellular materials into the trabecular meshwork. Elevated intraocular pressure also occurs if the drainage angle is physically obstructed by iris tissue and appositional angle closure occurs. Our inspection of the aqueous fluid and the structures involving the angle should rule out both cellular and physical obstructions.

GROSS EXTERNAL EXAMINATION

EXTERNAL EXAMINATION TO HELP IDENTIFY POSSIBLE OCULAR TRAUMA

Inspection should include gross examination for visible signs of any previous trauma.
These signs include the following:

- Facial and/or periocular scars from direct injury
- Lid ptosis
- Anisocoria (different size pupils) after iris sphincter tears
- Iridodialysis

Any reported trauma to the orbit or head should prompt the clinician to carefully inspect both grossly and with the slit-lamp microscope.

Trauma may cause glaucoma, even when no obvious signs of damage exist. Carefully evaluate the optic nerve in any patient with a history of trauma (consider q 6 months x 3 years and then annually if optic nerve and IOP remain stable).

EXTERNAL EXAMINATION OF THE IRIS COLOR

Gross inspection of the anterior segment is necessary to identify a rare but significant condition known as iris heterochromia (a difference in iris color between the eyes).

Heterochromia can indicate the following:

- Chronic uveitis
- Glaucomatocyclitic Crisis (Posner-Schlossman Syndrome)
- Fuchs' Heterochromic Iridocyclitis

Each of these conditions involves unique inflammatory processes which can lead to outflow insufficiency, increased IOP and eventual glaucoma damage.

UTILIZATION OF SLIT-LAMP BIOMICROSCOPY TO RULE OUT SECONDARY AND ANGLE CLOSURE GLAUCOMA

Glaucomatous anterior segment findings, while generally uncommon in primary open angle glaucoma, are strong indicators of various secondary open and angle closure glaucomas.

Abnormal characteristics of the cornea, conjunctiva, anterior chamber, iris and lens should heighten attention and scrutiny. It is important to recognize each of these signs to ensure accurate diagnosis and to assure proper follow-up care.

Visualize each tissue for abnormalities which can contribute to elevated intraocular pressure. Any materials which can decrease aqueous flow through the trabecular meshwork such as the following must be considered:

- Blood (red blood cells)

- Inflammatory cells (white blood cells, cytokines)
- High density proteins
- Pigment cells (pigmented iris epithelium)
- Fibrilo-granular materials (exfoliated lens particles)

ASSESSMENT OF THE CONJUNCTIVA / EPISCLERA / SCLERA

It is important to examine the anterior segment and to look for the following signs:

- Conjunctival hyperemia and ciliary injection
  - Dilated episcleral veins
    - Injection may represent acute or chronic episcleritis or scleritis which can cause inflammation
    - Careful examination of the conjunctiva and cornea for dry eye disease is important in glaucoma before starting treatment since treatment can exacerbate this condition significantly
- Diffuse injection
  - Diffuse injection occurs in cases of angle closure
    - Closure may be caused by appositional lens and angle morphology as well as neovascularization of the iris (NVI) with neovascularization of the angle (NVA)
- Circumlimbal injection (Flush)
  - Injection of the circumcorneal blood vessels rather than vessels in peripheral conjunctiva is usually secondary to uveitis/iritis which is a significant cause of inflammation

ASSESSMENT OF THE CORNEA

Examine the corneal tissue carefully for the following:

- Epithelial or stromal scars
- Endothelium pigment deposition
- Grey (Snowflake) deposition on the endothelium
- Keratic precipitates (KP)
- Edema

CORNEAL SCARRING

The presence of corneal scars is indicative of previous epithelial and stromal disruption from stromal keratitis infections e.g. herpetic and interstitial. Corneal scars can also be a result of previous trauma.

- All stromal disruptions can cause inflammation and subsequent scar tissue formation

CORNEAL ENDOTHELIUM PIGMENT

Pigment Dispersion Syndrome (PDS) is believed to be caused by contact between the iris pigment epithelium and crystalline lens zonular fibers. Friction liberates pigment into the anterior chamber where a vertically elongated linear deposition forms on the corneal endothelium.

The direction of aqueous flow through the pupil is responsible for the characteristic vertically oriented endothelial deposition that is termed “Krukenberg’s Spindle”

Pigmented cells circulate to the trabecular meshwork and block the aqueous outflow and thus causes elevated IOP and subsequent pigmentary dispersion glaucoma (PDG)

KRUKENBERG'S SPINDLE

Krukenberg's spindle appears as a vertically oriented pigmented line on the corneal endothelium (Figure 13.1).

Any signs of pigment on the endothelium warrants gonioscopic examination of the angle for PDS

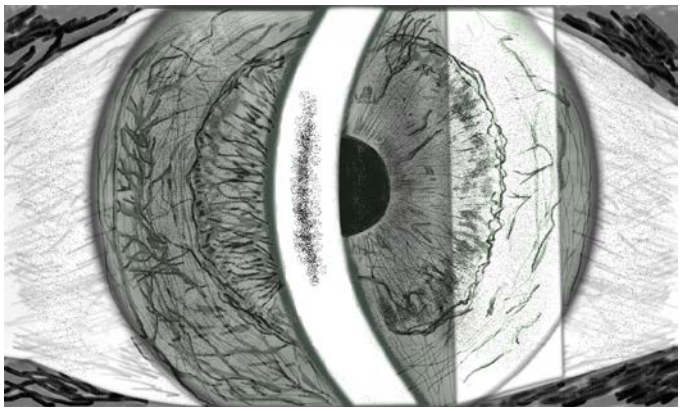

Figure 13.1: *Krukenberg's spindle on the posterior endothelium*

GREY "SNOWFLAKE" DEPOSITION

Exfoliated material liberated from the anterior lens circulates with the aqueous and into trabecular meshwork resulting in an increase in IOP.

The flake-like particles are occasionally found on the endothelium of the cornea. They are more easily visualized, however, near the iris pupillary margin. **Dilated** views of the lens zonules and anterior lens surface are **critical** to detect the deposits and then begin a full glaucoma work-up. Not dilating and looking at the lens is a common cause of missing a diagnosis of exfoliation glaucoma which has a different course and prognosis (worse) than primary open angle glaucoma.

KERATIC PRECIPITATES (KPS)

These accumulations on the corneal endothelium represent previous or current inflammatory cells that have been released into the anterior chamber. Since intraocular inflammation can have a substantial effect on IOP, recognition by the clinician of the presence of KPs is critical.

It is imperative to also identify the source of the inflammation whether localized or systemic in order to prevent future recurrences.

In Figure 13.2, note the diffuse accumulation of keratic precipitates (left image). The enlarged view (right image) illustrates both the round and stellate keratic precipitate variations.

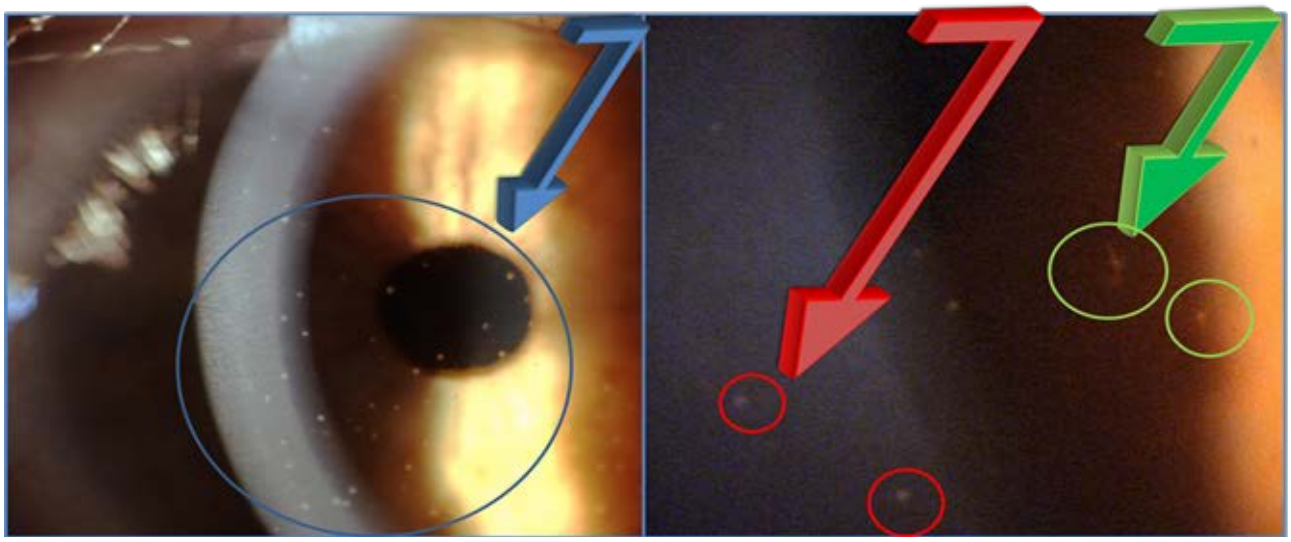

Figure 13.2: *Endothelial keratic precipitates*

CORNEAL EDEMA

The corneal endothelial pump functions to remove fluid continuously from the corneal stroma to maintain its transparency and ability to easily transmit light. In angle-closure glaucoma there is no available drainage pathway for aqueous fluid and this causes IOP to become significantly elevated. The forces resulting from building aqueous volume create enough pressure to overcome the capacity of corneal endothelial pump causing edema and severely reducing corneal transparency. Diffuse corneal edema is a strong indicator of severely increased IOP until proven otherwise.

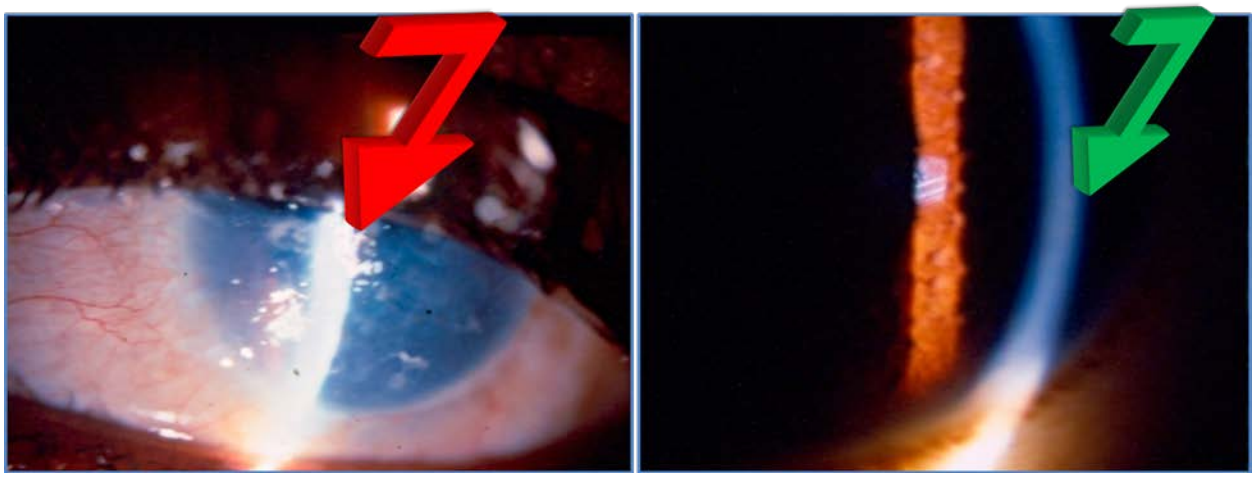

Figure 13.3: *Corneal clouding due to edema*

In Figure 13.3 note the loss of corneal transparency (left image) and widened slit-beam highlighting the corneal edema (red arrow) compared with the regular slit-beam width (right image) and clear view of deep anterior chamber structures (green arrow).

ANTERIOR CHAMBER

Examination of the anterior chamber should assess the depth of the chamber and the presence of any circulating cells, cytokines or proteins. A reduction in depth of the chamber can represent structural “crowding” between iris tissue and angle structures which can lead to complete angle-closure and potentially stop all aqueous outflow.

Disrupted cellular materials and proteins circulating in the anterior chamber eventually drain to the trabecular meshwork potentially slowing aqueous outflow and thus increasing IOP.

THE VAN HERICK TECHNIQUE

The van Herick technique provides an estimation of the anterior chamber depth and approximation of the openness of the chamber angle.

The clinician begins by positioning a non-dilated patient in the slit-lamp with the eyes in primary gaze. The slit-lamp light beam is narrowed to an optic section and positioned off-axis 60º from center for both temporal and nasal estimations. Starting on the temporal side, the beam is placed first at the limbus and then moved inward just until a shadow is created inside anterior chamber.

A comparison is then made between the width of the corneal optic section and the width of the shadow created between the corneal endothelium and the iris tissue. This is then repeated for the nasal angle.

CORRECT PLACEMENT OF THE OPTIC SECTION

In Figure 13.4, note the proper location of the slit-beam located just at the limbus (red arrow) but positioned inward just enough to cast a shadow inside the anterior chamber as shown in the magnified inset with the green arrow.

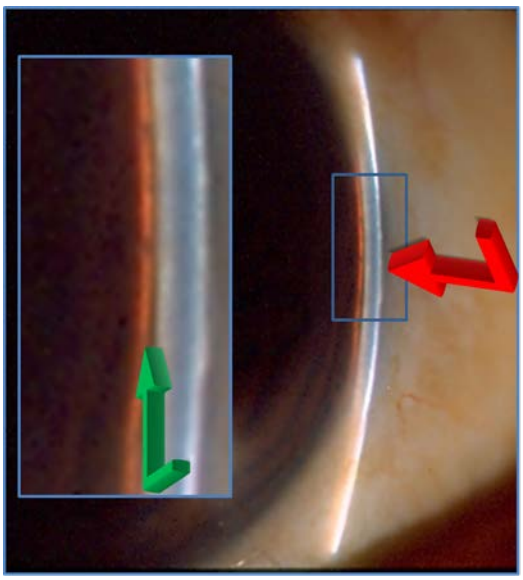

Figure 13.4: *Positioning the optic section for the van Herick Test*

THE VAN HERICK GRADING SYSTEM

The van Herick estimation of the anterior chamber depth using an optic section is graded according to the chamber shadow (CS) width compared to corneal thickness (CT) width (Table 1 and Figure 13.5).

Classification	(Depth)	Anterior Chamber Depth	Figure
Grade 4	(Wide Open)	CS >= 1 CT	A
Grade 3	(Open)	CS = 1/3 to 3/4 CT	B
Grade 2	(Narrow)	CS = 1/4 CT	C
Grade 1	(Very Narrow)	CS < 1/4 CT	D

Table 13.1: *Grading with the van Herick Test*

All Grade 1 & 2 angles should have gonioscopy performed to assess the angle anatomy and to exclude any risk of angle closure.

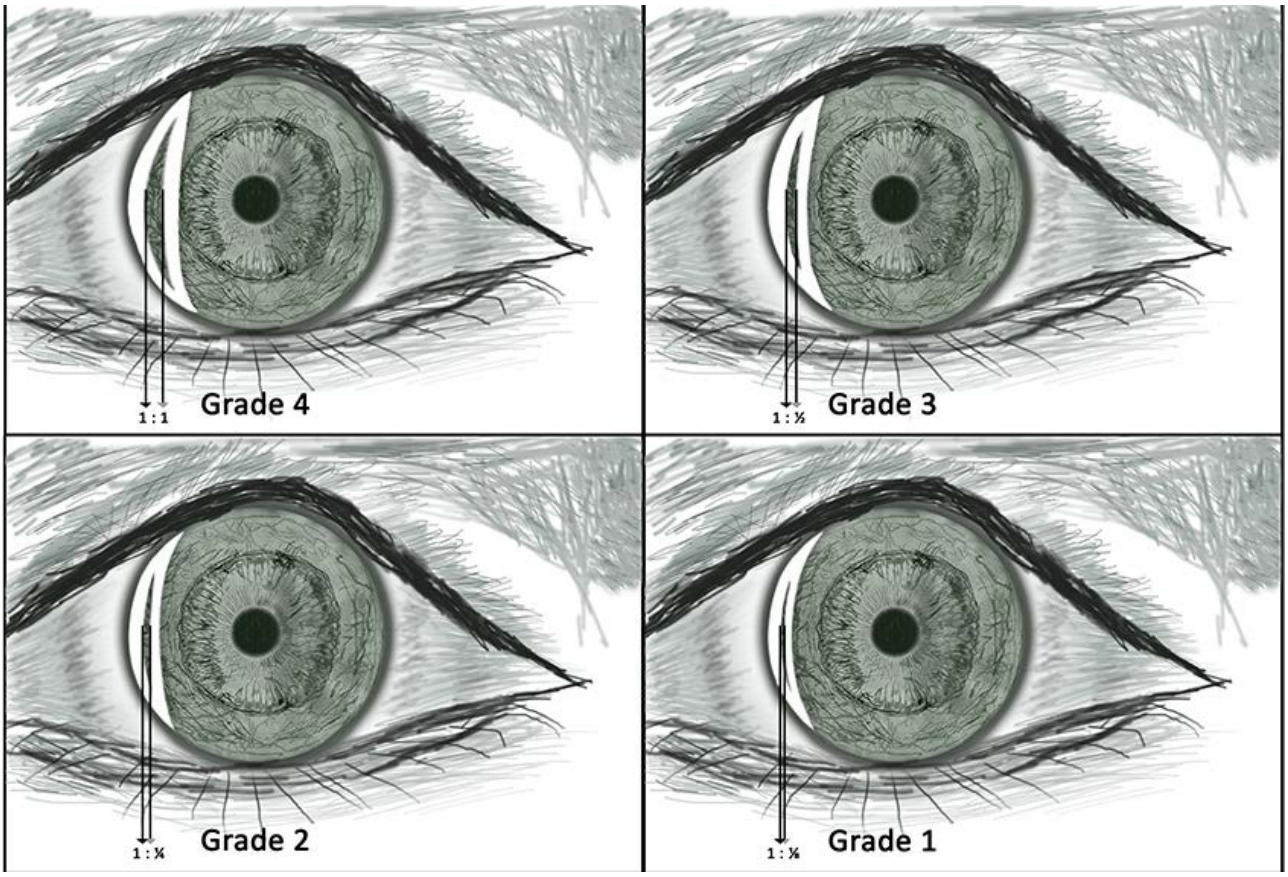

Figure 13.5: *Clockwise from top left: Grade 4 angle, Grade 3 angle, Grade 1 angle, Grade 2 angle*

An example of a Grade 1 angle is shown in Figure 13.6. In the magnified inset compare the corneal thickness (CT) width (blue arrow/line) to the anterior chamber shadow (CS) width (green arrow/line). The width of the created shadow is less than ¼ of the corneal optic section.

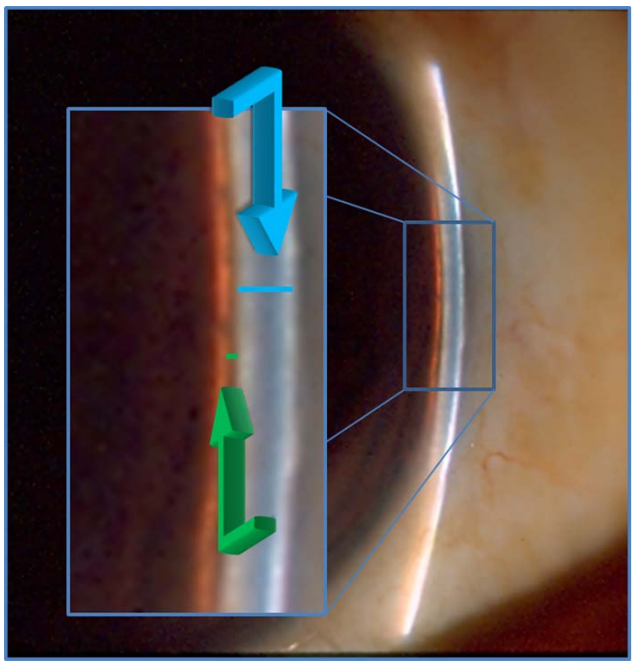

Figure 13.6: *A Grade 1 anterior chamber angle*

ANTERIOR CHAMBER DEPTH

After completing the van Herick angle estimations, the clinician should “sweep” the slit-lamp light beam across the entire cornea. This technique determines the anterior chamber depth beyond the limbus.

It is useful in detecting narrowed chambers around the mid-peripheral iris due to forward iris bowing in Pupillary Block Glaucoma and shallow chambers commonly seen in Phacomorphic Glaucoma.

Figure 13.7 shows normal, deep chamber shadow (blue arrow) compared with significantly shallower anterior chamber (red arrow). Note the mid-peripheral location of the slit beam to achieve the chamber depth estimation.

Figure 13.7: *Normal (left image) and shallow anterior chamber (right image)*

CELLS AND FLARE

Cytokines, cells and proteins (flare) are of great concern in anterior segment examination for glaucoma. Infection, trauma, localized and systemic inflammatory conditions can release cytokines and proteins responsible for elevated IOP and potential glaucoma.

Anterior chamber inflammation is very difficult to detect without proper technique, so establishing excellent technical skill in this area is critical for accurate assessment of the presence of cells and flare in the chamber. Visualization of cells and flare does improve with each additional experience and continued use of optimum techniques.

It is important to remember that since aqueous is constantly circulating in the chamber, so too will any cells or cytokines contained within the chamber. Being properly focused inside the anterior chamber and then “parking” the light beam without movement to observe any circulating cells is critical.

All anterior chamber examinations need to be done prior to any instillation of fluorescein as the fluorescein may penetrate the cornea into the anterior chamber and mimic flare.

Clinicians should always distinguish between white cells, red blood cells and/or pigmented cells circulating in the aqueous.

The following is a good technique to adopt for anterior chamber evaluation:

- Turn room lights “off”
- Patient looking straight
- Set illumination level to highest setting possible
- Position the slit-lamp light 30-40 degrees “off-axis”
- Beam height set to 1 mm wide x 3 mm long
- High magnification is used
- “Fixed” focus just between iris and cornea
    - Tip: place cornea into focus, then the iris; now pull back slightly so neither are in focus and then you are in the middle of the anterior chamber

Decrease the beam size to 1mm x 1mm and attempt to count the number of cells visualized when any cells or flare are noted.

Table 13.2 shows a grading scale for anterior chamber inflammation evaluation.

	Cells	**Flare**
Grade 0	No Cells Visible	No Flare Visible
Trace	1-4 Cells noted	Trace noted
Grade1	4-8 Cells noted	Mild Flare
Grade2	9-15 cells noted	Moderate
Grade3	too many to count	Marked
Grade4	obscures iris detail	Severe

Table 13.2: *Grading scale for cells and flare in the anterior chamber*

In Figure 13.8 notice how neither the crystalline lens (blue arrow) nor the cornea (red arrow) are in focus. When focused in the chamber, attempt to visualize as many scattered white cells in the anterior chamber (green box/arrows) using a 1mm x1mm beam. The example shown indicates a Grade 3 Cells i.e. too many to count.



Figure 13.8: *Focusing in the anterior chamber*

HYPHEMA

Red blood cells or blood in the anterior chamber constitutes hyphema. Most commonly hyphema is the result of a blunt force trauma.

Rarely, disruption to blood vessels at the ostium in trabeculectomy surgery can occur and result in hyphema formation.

In addition to surgery or trauma, hyphema can occur from the following:

- Sickle cell anemia and other blood dyscrasias
- Neovascularization of iris and angle
- Intraocular lens implant/iris chafing
- Herpes zoster kerato-uveitis
- Excessive use of ethanol or anticoagulants

Traumatic tears in the circular and longitudinal muscle fibers of the ciliary body may rupture the major arterial circle of the iris releasing blood into the anterior chamber.

Non-traumatic causes result from surgical damage to blood vessels or increased permeability of arterioles that allow red blood cells to release into the chamber.

Any level of circulating red blood cells constitutes a “hyphema,” although more significant levels of blood and repeated episodes (rebleeding) increase the risk of elevated IOP and subsequent development of glaucoma.

All cases of hyphema require the implementation of measures to prevent rebleeding including restriction or discontinuation of anticoagulants including aspirin, warfarin, Coumadin and the use of ethanol.

Patients are placed on limited activity, sleeping with the head upright and elevated. Strong mydriasis with 1% atropine BID can be helpful and, if traumatic, gonioscopic evaluation performed at 1 week to look for angle recession is required. If the IOP is elevated, daily follow-up is required until resolution occurs.

IRIS

An iris is constantly moving to adjust the pupil aperture in response to varying levels of illumination. Mechanical or traumatic events can damage the delicate tissue of the iris.

IRIS TRANS-ILLUMINATION DEFECTS

Areas of the iris may thin from mechanical “friction” due to abnormal iris and lens morphology. The pigmented epithelium cells of the iris can be disrupted due to contact with bundles of anterior zonular fibers of the lens leading to trans-illumination defects.

Visualization of these pigmented cells and materials likely indicates that they have been liberated from the mid-peripheral radial iris. The defects are often arranged in a spoke pattern since the lens zonules are positioned in this bicycle-wheel pattern.

Techniques to evaluate the iris for such defects to assist in the accurate assessment include the following:

- Place a decreased slit-beam height to “fit” inside the pupil without illuminating any anterior iris features
- Use full illumination lighting and position slightly “off-axis” to produce a bright red reflex in the pupil
- With a darkened examination room, search for “red” slits at the peripheral iris (Figure 13.9) where iris/lens contact most often occurs

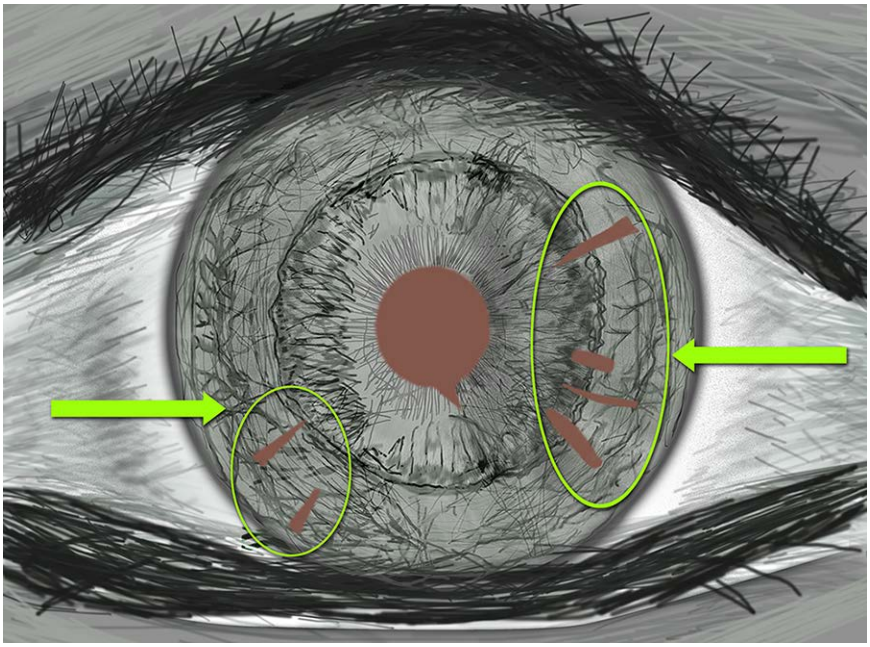

Figure 13.9: *Note the areas of spoke-like slit trans-illumination defects (green arrows/circles)*

EFFECTS OF OCULAR TRAUMA ON THE IRIS

Blunt force trauma to the eye can cause significant changes to the iris structure. Anisocoria and iridodialysis may be induced by trauma.

- Anisocoria can result from traumatic iris sphincter tears.
    - Normally, the sphincter pupillae is responsible for miosis, or constriction of the pupil
    - Damage to the sphincter can cause the traumatized eye to be larger compared with the fellow unaffected eye
    - The pupillary displacement will often point towards the location of the sphincter tear
    - In addition to the irregular sized and shaped pupil, iris sphincter muscle damage can also reduce reactivity producing a relative afferent pupillary defect (RAPD)
- Iridodialysis can result from disinsertion of the iris from the scleral spur.
    - Scleral spur structure is made of collagen tissue and is located posteriorly and adjacent to the trabecular meshwork
    - Ciliary body structure is located posteriorly and adjacent to the scleral spur tissue
    - Iris root normally anchors into the anterior portion of the ciliary body along the scleral spur
    - Iris root detachment subsequently damages trabecular meshwork and intraocular pressure can rise significantly

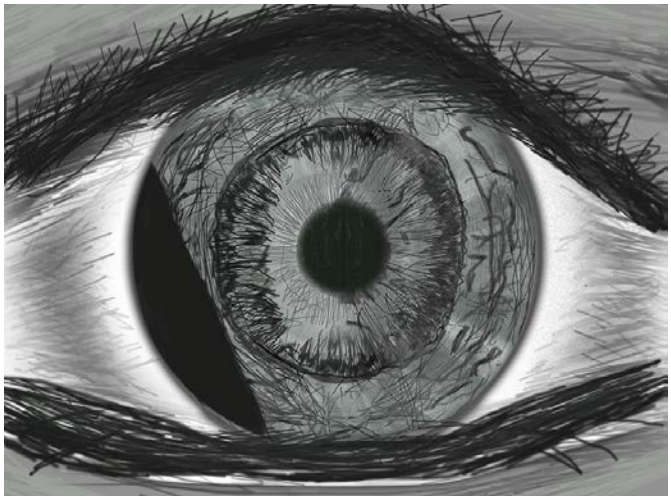

Figure 13.10: *Complete disinsertion of the iris root from the scleral spur at the limbal interface*

NEOVASCULARIZATION OF THE IRIS (NVI)

Careful inspection of the iris/pupil border for neovascularization is critical, especially in patients with a history of vaso-occlusive diseases such as:

- Diabetic retinopathy
- Central retinal vein or artery occlusion
- Carotid occlusive disease (ocular ischemic syndrome, OIS)

Rarely, NVI can also occur in patients with a history of the following:

- Retinal vascular diseases
- Blood dyscrasias, hemoglobinopathies (Sickle-cell anemia)
- Chronic uveitis

- Chronic retinal detachments
- Intraocular tumors

Patients with longstanding and poorly controlled diabetes are at increased risk for NVI.

It is critical to detect any iris neovascularization as early as possible. Once a fibrovascular membrane proliferates from the iris surface to anterior chamber angle structures it can quickly contract to create peripheral anterior synechiae adhesions and block aqueous outflow. Once outflow is blocked, the IOP rises dramatically and reduction efforts are often ineffective.

All high-risk patients should also have gonioscopy performed even when no NVI is visualized as neovascularization of the angle can occur without NVI.

In Figure 13.11, observe the fine blood vessels located at the pupillary frill and radiating toward the angle. These vessels can be very fine and overlooked early in their course – high magnification and careful attention is required to observe them. This process needs to be done on a **NON-DILATED iris**

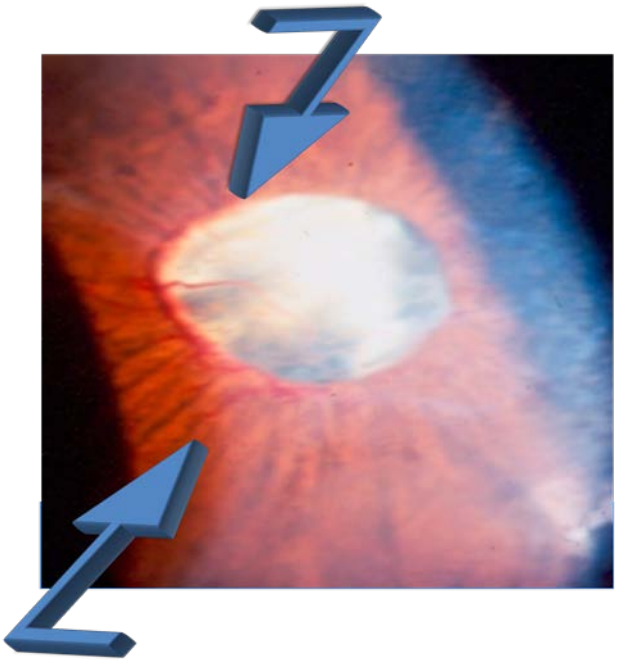

Figure 13.11: Neovascularization of the iris

EFFECTS OF ELEVATED IOP ON THE IRIS

Pigment dispersion, pseudo-exfoliation, inflammation, and traumatic disruption to trabecular meshwork can result in elevated IOP. However, primary or secondary angle closure attacks will raise pressure most dramatically.

During periods of substantially elevated IOP, the pressure creates infarction within iris vessels and a subsequent inflammatory cytokine release occurs. Infarction and ischemia of the iris sphincter and dilator muscles decreases tonus and control of pupillary responses. The end result is often a mid-dilated pupil with poor response to light stimuli.

EFFECTS OF INFLAMMATION ON THE IRIS

Anterior chamber inflammatory cells can cause two types of synechiae (abnormal adhesions between iris and adjacent tissues):

- Anterior – adhesion between iris and cornea leading to angle-closure conditions (see Gonioscopy chapter)
- Posterior – adhesion between posterior iris and the anterior lens (see Lens section)

Posterior synechiae can be visualized with the slit-lamp and can indicate chronic inflammation from uveitis/iritis.

CRYSTALLINE LENS AND GLAUCOMA

While examination of the lens can be performed prior to dilation, only features of the central lens are observable with the slit-lamp. **It is significantly more valuable to view the lens after dilation to uncover diagnostic information that is useful for glaucoma evaluation.**

Additionally, evidence of a posterior synechial adhesion between the posterior iris and anterior lens is sometimes only discovered following dilation where remnants of iris adhesions remain behind on the lens after a previous synechiae has been "broken".

POSTERIOR SYNECHIAE

Evidence of previous or existing posterior synechiae can be visualized as an irregular or poorly dilating pupil. Usually, irregular pupils will demonstrate attachment points between lens and iris creating a "clover-like" shape to the pupil.

Partial points of synechiae are an indicator of recurrent ocular inflammation and must be monitored carefully.

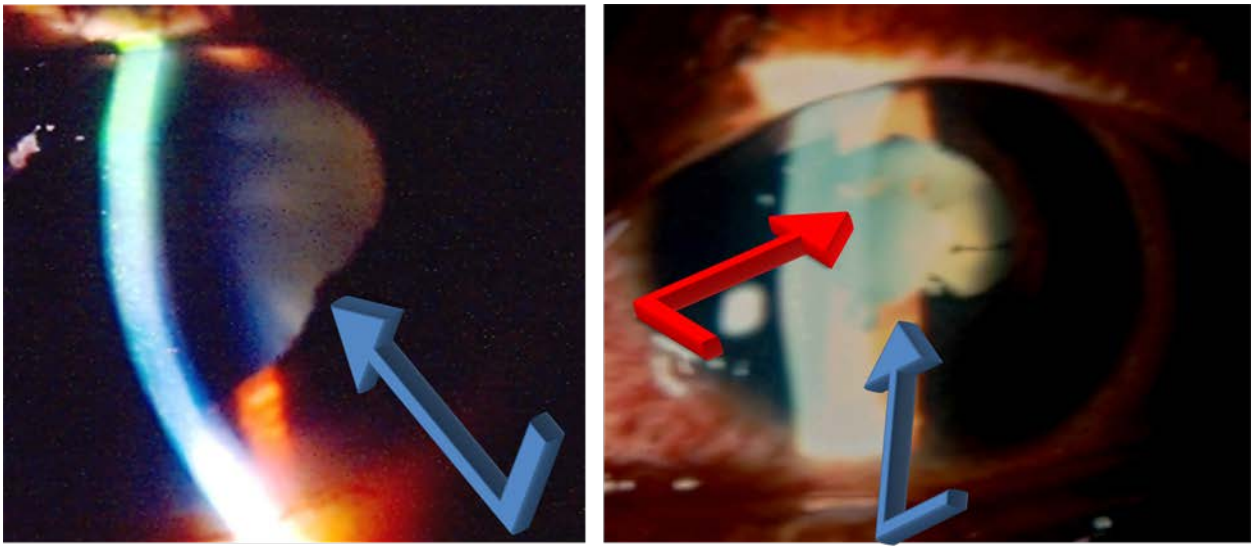

Figure 13.12: *Posterior synechiae signs*

Figure 13.12 demonstrates the synechia attachment points and "clover-like" appearance (blue arrows) and the synechiae remnants attached to the lens (red arrow).

When a complete 360º synechial attachment occurs, it causes a secondary type of glaucoma termed "pupillary block" glaucoma. The adhesions when completely circumferential "trap" aqueous behind the iris structure, bowing the iris forward to appositionally close the angle.

A peripheral iridotomy is required to alleviate the pupillary block and allow the iris to "fall back" away from the angle drainage system.

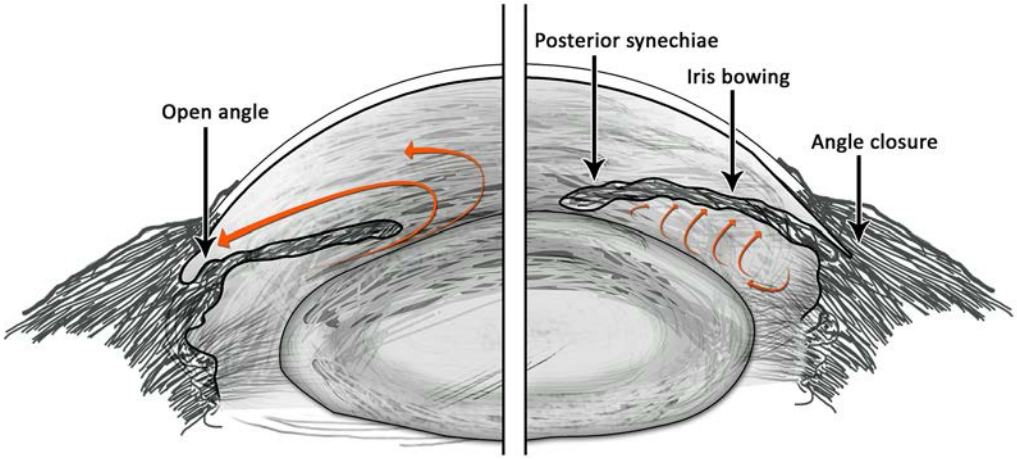

Figure 13.13: *Closed angle due to pupillary block.*

Figure 13.13 demonstrates the difference in flat iris positioning (left) allowing normal aqueous outflow compared with the iris bowing (right) due to pupillary block from a posterior synechiae.

EXFOLIATION

- Pseudo-exfoliation/Exfoliation can elevate IOP more significantly than open-angle normals
- The material can collect on the lens surface, leaving a central gray "zone," mid-peripheral clear "zone" and occasionally another far peripheral gray "zone"
- Presence of exfoliative material indicates increased risk of glaucoma development

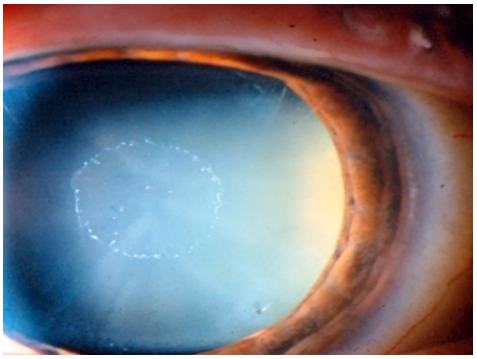

Figure 13.14: *Exfoliative material on the anterior lens surface (Note the central gray "zone" with clear mid-periphery)*

CATARACTS

- Changes in appearance to the lens can be useful in identifying an underlying source such as previous trauma or ongoing use of certain systemic medications
    - **Rosette**: Traumatic cataracts, termed "rosette" due to the flower-like appearance (Figure 13.15), indicate ocular injury
    - **Posterior Sub-capsular Cataract (PSC)**: Prolonged corticosteroid use causes PSC cataract; some patients are susceptible to elevated IOP
    - **Glaukomfleken Cataract**: Significant "spikes" in IOP cause these irregular white opacities located in the anterior portion of the lens

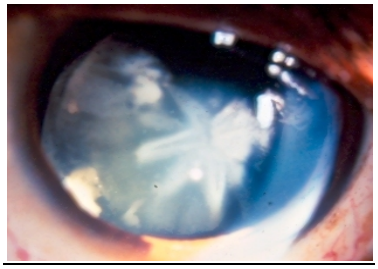

Figure 13.15: *Traumatic rosette cataract (note the petaloid or star-shaped cataract)*

NUCLEAR CATARACTS

Mature vs. Hypermature Nuclear Cataracts:

- Mature cataracts are classified as nuclear opacities dense enough to obscure any view of the posterior lens or posterior chamber of the eye
    - Associated with Phacomorphic Glaucoma – mature cataracts undergo anterior movement which results in forward displacement of iris tissue causing a shallower anterior chamber and "secondary block" of aqueous outflow then occurs
- Hypermature (Morgagnian) cataracts occur when the nuclear cortex protein liquefies and leaks into the chamber giving a "wrinkled" appearance to the crystalline lens
    - Phacolytic glaucoma can occur if this protein "clogs" the trabecular meshwork and raises the IOP

SUMMARY

- Use of the slit-lamp biomicroscope can be very useful in detecting cellular or structural changes in the anterior segment
- The trabecular meshwork serves as the point of outflow for aqueous making it susceptible to compromise and damage from various anterior chamber pathologies
- Clinicians must be alert for those changes in order to properly assess inherent risk of glaucomatous optic neuropathy
- The slit-lamp evaluation often highlights conditions that can affect the trabecular meshwork angle
- It is critical to perform gonioscopy to further understand the possible structural changes that may have occurred
- Technical skill and experience will allow for accurate assessment and proper follow-up care