# RADIOLOGICAL EXAMINATION OF THE VISUAL SYSTEM

## AUTHOR

**Luigi Bilotto:** Brien Holden Vision Institute

## PEER REVIEWER

**John Pula:** NorthShore University Health System, Pritzker School of Medicine Clinician Educator, University of Chicago

## RADIOLOGICAL EXAMINATION

Radiological examination refers to procedures that employ the use of imaging techniques to visualize the human body non-invasively for diagnostic or therapeutic purposes. The most common techniques used in ocular care are Magnetic Resonance Imaging (MRI) and Computed tomography (CT)

### PROJECTIONS

Images are 2 dimensional pictures which can run in any of three planes.

- Axial (or transverse) plane - a horizontal plane of view. This is the only slice seen on most head CT scans. Orbit CT scans usually include coronal or sagittal scans as well. Axial images account for the majority of sequences in a brain MRI as well.

- Coronal plane - a vertical plane, named from the ‘corona‘ or ‘crown‘ as seen in many paintings displaying saints or holy men. The optic nerves, superior and inferior recti muscles, paranasal sinuses, orbital floor and roof, and optic chiasm are all seen in this plane.

- Sagittal plane - a vertical plane of view running anterior to posterior.

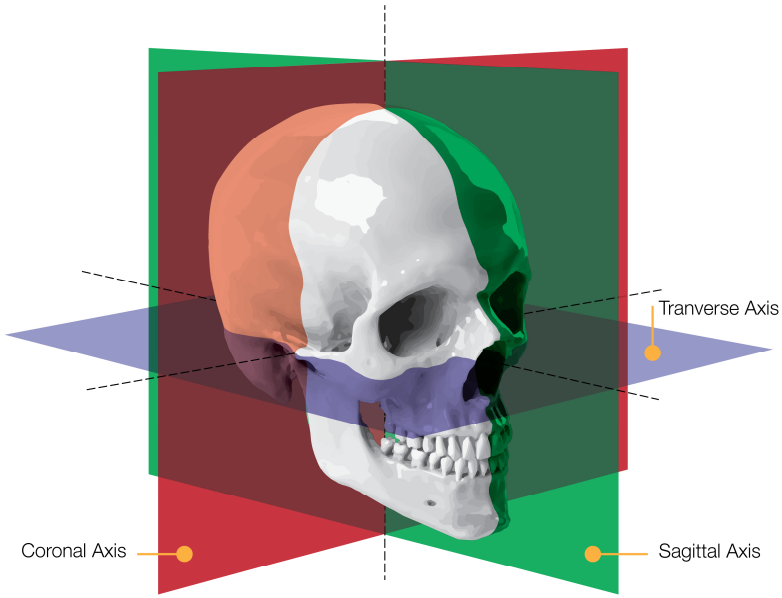


***Figure 18.1. Diagram showing sagittal, coronal and transverse planes of the head***

## I. MAGNETIC RESONANCE IMAGING

Within the body, hydrogen nuclei (protons) act as small magnets when placed in a strong magnetic field. Each proton can exist in one of two states - parallel or antiparallel. When a magnetic field is activated, in an MRI machine for example, all protons are affected, and are aligned in a similar direction (i.e. parallel). At this point, a pulse of energy can be sent to the protons, and their reaction to the pulse (time constant) produces a signal that is captured by an imager, decoded and represented as a gray scale in a scan (the MRI images). The images are essentially imaged "slices".

The most commonly used time constants are T1 and T2. T1 is the time needed for 63% of protons to recover their former position after a pulse is given (relaxation time). Different types of tissue (i.e. extraocular muscle, optic nerve) have different T1 relaxation times, and this is represented by having different intensity (brightness) on MRI. T1-weighted imaging is the best sequence on MRI to evaluate normal anatomy.

T2-weighted imaging uses different imaging parameters (relaxation) than T1-weighted imaging to change the relative intensity of the signal coming from certain tissues. Specifically, pathologic lesions are usually visualized better with T2-weighted imaging.

Other relevant techniques include diffusion-weighted MRI which allows the visualization of water diffusion in biological tissues and gradient imaging which allows finer tuning to allow imaging of blood. In the orbits, a special sequence, fat suppression, is used to eliminate signal from the orbital fat, in order to better visualize the intra-orbital contents.

Evaluations thus consist of several sequences of images from the same slice of tissue. These usually include T1-weighted (for anatomy), T2-weighted (for pathology), diffusion-weighted (for ischemia), and gradient imaging (for blood).

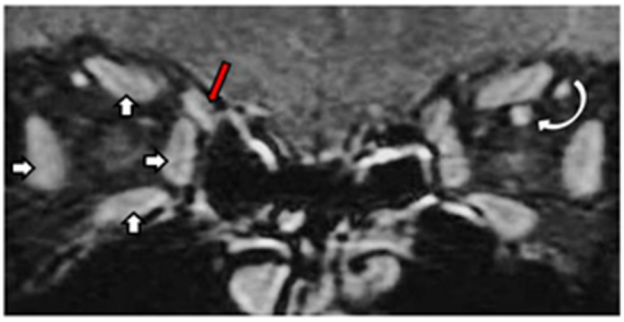

***Figure 18.2.*** *Coronal fat-suppressed T1-weighted imaging of the orbits. Short arrows point to the rectus muscles. Long arrow shows the superior oblique muscle. Curved arrow shows an ophthalmic vessel.*

## II. COMPUTED TOMOGRAPHY

The principles of X-ray are used for CT scans. X-rays refer to the use of an electromagnetic wave of high energy and very short wavelength which is able to pass through many opaque materials including the human body. X-rays are absorbed to different degrees by materials of varying composition and physical density. Therefore if an X-ray beam is passed through a portion of matter (body, globe, etc.) it will be attenuated according to the density of the area. Sensitive detectors can then capture and record the residual X-rays on a photographic or digital image.

Tomography means imaging a number of (X-ray) sections together. Scanning cross-sectionally will provide a "slice" of the anatomy. A series of these "slices" are then repeated at various levels. An image representing tissues and structures can be computer generated.

CT scans are better for the detection of denser tissues. Substances which appear bright on CT are therefore tissues such as bone and acute blood. In the orbit, drusen are also dense (Figure 18.3).

***Figure 18.3.*** *Axial CT image through the orbits, showing the dense appearance of optic disc drusen (arrowhead).*

## III. CONTRAST

Contrast agents or media may or may not be given as part of the imaging sequences. Given orally or intravenously, contrast agents alter the relaxation times of atoms within body tissues where they are present. They thus accentuate

the appearance of certain structures, namely those which have either physiologic or pathologic breakdown of the blood-brain barrier. Common pathologic examples of these are tumors or abscesses.

The contrast used for CT is an iodine-based dye. The contrast used for MRI is an element called gadolinium which is iodine free. Neither MRI nor CT contrast is used in patients with renal failure, either because it can worsen renal function (iodine), or cause a skin problem (gadolinium). For MRI, gadolinium is given with T1-weighted imaging.

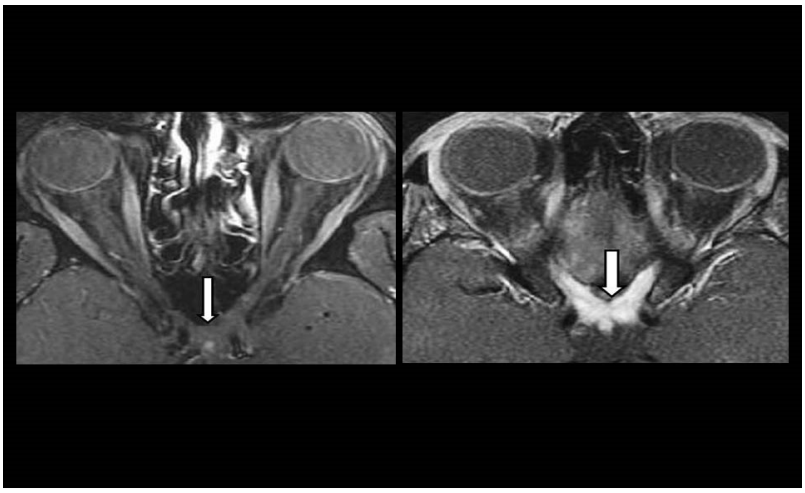

***Figure 18.4.*** *T1-weighted gadolinium contrast evaluations of the chiasm, showing a normal, non-enhancing chiasm (left image), and a pathological, demyelinating chiasm lesion (right image), which appears hyperintense on MRI.*

## IV. ADVANTAGES/DISADVANTAGES OF CT VERSUS MRI

*CT*

- Shorter examination scanning time
- Quieter procedure
- Larger open area decreases claustrophobia
- May be utilized in patients with intra-ocular metallic foreign bodies
- Pacemakers are unaffected
- Bone and small fractures more easily seen

*MRI*

- No radiation
- Orbital muscles and fat easier to distinguish
- Superior evaluation of most orbital and intracranial lesions

## V. STUDY OF CHOICE: CT VERSUS MRI

| Area of suspected pathology | CT | MRI |
|---|---|---|
| Blow-out fracture | • | |
| Extraocular muscles | | • |
| Fracture (craniofacial) | • | |

| | | |
|---|---|---|
| Lacrimal gland mass | • | • |
| Mass (craniofacial) | • | • |
| Optic nerve | | • |
| Chiasm | | • |
| Cerebral lesions (figure 4) | | • |
| Cerebral hemorrhage (acute) | • | |
| Cerebral hemorrhage (chronic) | | • |
| Vascular malformation | | • |

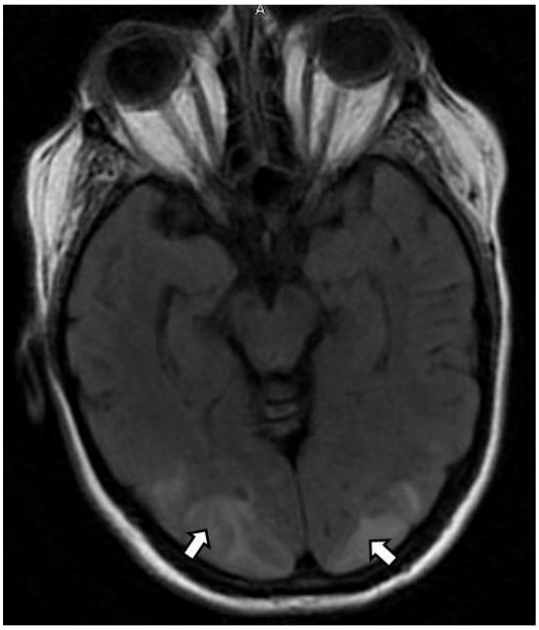

***Figure 18.5.*** *Axial non-contrast MRI of the brain showing pathological lesions in the occipital lobes (arrows), resulting in cortical blindness. Ocular examination and orbital imaging in this case would be normal, accentuating the need for correct localization prior to image ordering.*

## VI. GENERAL GUIDELINES FOR IMAGING OF VISUAL PROBLEMS

- First localize the lesion, then the suspected pathology
- Choose the study (CT versus MRI) and location (brain versus orbit) based on above
- Order contrast based on indications and contraindications
- Discuss the case with radiology/neuro-radiology to increase yield of discovering pathology.
- A normal imaging result does not necessarily mean that there is no pathology (lesions may be too small to be seen, may be iso-intense or iso-dense to surrounding tissues, or may be too short lived to yet be present on imagine (for example, a small stroke on MRI).

## REFERENCES

1. Johnson M, Policeni BA, Lee AG, Smoker WR. Neuroimaging in Ophthalmology. Oxford University Press, New york, 2011.
2. Lee AG, Brazis PW, Garrity JA, White M. Imaging for neuro-ophthalmic and orbital disease. Am J Ophthalmol 2004;138(5):852-862.