BrienHoldenVisionInstitute

FURTHER STRABISMUS DIAGNOSES

AUTHOR

Tim Fricke

PEER REVIEWER

Shrikant Bharadwaj: LV Prasad Eye Institute

CHAPTER CONTENTS

CLASSIFICATION 2
ASSESSMENT 2
EXAMPLES OF FURTHER CONDITIONS CAUSING STRABISMUS 3
NEUROGENIC STRABISMUS 3
THIRD CRANIAL NERVE PALSY 3
FOURTH CRANIAL NERVE PALSY 5
SIXTH NERVE PALSY 7
MECHANICAL STRABISMUS 9
CLASSIFICATION 10
BROWN'S SYNDROME 10
TED- THYROID EYE DISEASE 11
DUANE'S SYNDROME 13
ORBITAL TRAUMA 15
MYOGENIC STRABISMUS 16
CHRONIC PROGRESSIVE EXTERNAL OPHTHALMOPLEGIA (CPEO) 16
MYASTHENIA GRAVIS 17
LERS- LAMBERT EATON ROOKE SYNDROME 19
OCULAR MYOSITIS 19
ALBINISM 20
RETINAL DISORDERS (NEEDING MEDICAL ASSESSMENT) 20

RETINOBLASTOMA 20
CHORIORETINAL DEGENERATIONS 22
SUMMARY OF DIAGNOSIS OF STRABISMUS DISORDERS 23
REHABILITATION OPTIONS FOR INCOMITANT STRABISMUS 23
MICROTROPIA 23

CLASSIFICATION

- Strabismus can be an important direct or indirect sign of ocular or neurological disease including trauma, palsy, neoplasm (e.g. retinoblastoma, rhabdomyosarcoma) or vascular accident
- In additon to esotropia and exotropia diagnoses, less common forms of strabismus can also present
- These less common forms of strabismus are usually **incomitant** (where the strabismus varies in size with direction of gaze), and have a wide variety of causes
- They can be **congenital**
    - Usually due to developmental anomaly of the motor system
    - Anatomy of muscle or nervous system supplying them
- They can be **acquired**
    - Caused by injury or disease of ocular motor system
    - May be longstanding/static- no medical attention
    - Active- needs urgent referral for medical attention

FEATURES OF THESE STRABISMUS DIAGNOSES

- Angle of deviation increases as the eyes turn in the direction of the limitation of movement
    - Except in mechanical palsies when movement limited in opposing directions
- Angle decreases as eye moves in opposite direction
- Deviation differs depending which eye is fixating
    - Cover test in primary position: if size of deviation differs when each eye is covered, may indicate incomitant deviation
    - This is due to extra innervation of the paretic muscle

ASSESSMENT

- If a parent says that their child's eye "sometimes looks funny", but there is no sign of strabismus during your examination, assume there is an intermittent strabismus until proven otherwise
- Cycloplegia and pupil dilation should be completed for any first presentation of a strabismus
- If you can't identify a satisfactory cause of strabismus, refer to the most appropriate person for further diagnostic (and/or management) opinion. If you can satisfactorily diagnose one of the benign forms of strabismus, manage as per the Esotropia and Exotropia chapters.

EXAMPLES OF FURTHER CONDITIONS CAUSING STRABISMUS

- **Neurogenic (nervous innervation dysfunction)**
  - III (Oculomotor nerve)- superior rectus, inferior rectus, medial rectus, inferior oblique
  - IV (Trochlear nerve)- superior oblique
  - VI (Abducens nerve)- lateral rectus
- **Mechanical (physical restriction or displacement)**
  - Duane's, Brown's, thyroid eye disease (TED), Orbital injury, Orbital tumours
- **Myogenic (muscular dysfunction)**
  - Myasthenia gravis, chronic progressive external ophthalmoplegia (CPEO), Orbital Myositis, Rhabdomyosarcoma
- **Other**
  - Albinism, monocular vision loss, hemi-facial asymmetry

NEUROGENIC STRABISMUS

THIRD CRANIAL NERVE PALSY

- Most third nerve palsies are unilateral, and can be classified as:
- **Complete**
  - Paralysis of all extraocular and intraocular muscles supplied by IIIrd nerve:
  - superior rectus, inferior rectus, medial rectus, inferior oblique, Levator, Sphincter Pupillae, Cilary Muscle
- **Incomplete/Partial**
  - Paresis of all extraocular muscles but not inferior oblique muscle
  - Paresis of a group of muscles- inferior or superior division
  - Single muscle palsies

AETIOLOGY

- Acquired infranuclear lesions
  - Compression by posterior communicating artery anerysm
  - Adjacent tumours
  - Occlusive vascular disease- diabetes or hypertension
  - Closed head injury

SYMPTOMS

- Pain around eye
- Headache
- Sudden and rapid onset of palsy
- Exotropia –hypotropia (eye “down and out”)
- Ptosis
- Diplopia (if ptosis partial or absent)
- Dilated pupil

INVESTIGATION

- Medical Investigation- neurosurgical
- Ophthalmic and orthoptic investigation
- Pupil reaction - is it dilated? How well does it react?
- Accommodative palsy?
- Integrity of other cranial nerves: IV, VI, V (corneal sensitivity)
- Cover test- exotropic, intorted and hypotropic
- Ptosis?
- Visual acuity- congenital III nerve palsy, gross amblyopia due to ptosis
- Ocular movement- overaction of the synergistic muscles of the unaffected eye, further sequelae not formed
- Measurement of deviation

MANAGEMENT

- Refer for medical work up of the cause of the palsy
    - This is **urgent** if symptoms suggest recent onset
    - There is little point if symptoms suggest the palsy is stable & longstanding

Ocular considerations

- Visual acuity – treatment of amblyopia in congenital palsies
- Symptoms – prisms, although of little use unless palsy is mild
- Photophobia –constriction of pupil with pilocarpine 0.1% x 2 daily
- Surgical –must be delayed 9-12 months until stable in acquired palsies→ ASAP in congenital palsies

FOURTH CRANIAL NERVE PALSY

- Supplies superior oblique only
- Most frequently diagnosed form of vertical strabismus
- Lesions affecting IVth nerve result in problems with
    - Depression
    - Intorsion
    - Abduction

AETIOLOGY

- Congenital (about 75%)
- Acquired
    - Trauma – particularly bilateral cases
    - Vascular
    - Diabetes
    - Space occupying lesion

INVESTIGATION

Case history

- Symptoms much worse in acquired than congenital
- Image tilt is an important feature
- Patient complains of vertical diplopia, worse in down gaze (e.g. when reading)
    - Superior oblique known as the 'reading muscle', px may complain of having to hold book higher
    - Varifocals/bifocals contraindicated

Abnormal head position / diplopia

- Head tilt to unaffected side
- Possibly face turn to unaffected side and chin depression

Cover test

- Hypertropic and slightly esotropic
    - Increases on near vision
    - Measure size of deviation (prism bar) for accurate record
    - Only slight hypertropia in primary position if bilateral palsy
    - Presume the condition is bilateral until proven otherwise in acquired (usually due to trauma), can be asymmetric
    - Extorsion present in acquired bilateral palsies (not congenital)

Ocular motility

- Underaction of affected superior oblique, overaction of contralateral inferior rectus
    - Muscle sequelae will be formed in congenital, not in acquired
    - Greatest hyperdeviation seen when eye looks up and in due to muscle sequelae, overaction of inferior oblique (doesn't follow normal pattern)
- Use Park's Three Step test to identify:
    - **Step 1**: Which eye is "higher" (hypertropic) in primary gaze?
    - **Step 2**: Is the hypertropia worst in left or right gaze?
    - **Step 3**: Is the hypertropia worst when the head is tilted to the left or to the right?

Binocular function

- Large vertical fusional range in congenital (10Δ or more!)
- Suppression in congenital?

Hess Chart / Field of Binocular single vision

- Hess is smaller for affected eye in acquired, congenital, more equal in size due to muscle sequelae

SUPERIOR OBLIQUE PALSY OR SIMULATING LESION?

- Remember that it is difficult to distinguish a superior oblique palsy from a 4th cranial nerve palsy and several other conditions (including orbit shape abnormalities)
    - So clinical diagnosis is often "superior oblique palsy or simulating lesion"
    - Laboratory tests such as cover test scans are often needed to find the actual cause (refer to ophthalmology with your descriptive diagnosis "superior oblique palsy or simulating lesion")
- Something that will look like cranial nerve IV
    - Extorted right orbit and globe will cause a V-pattern and a bilateral (apparent) inferior oblique overaction (OA)

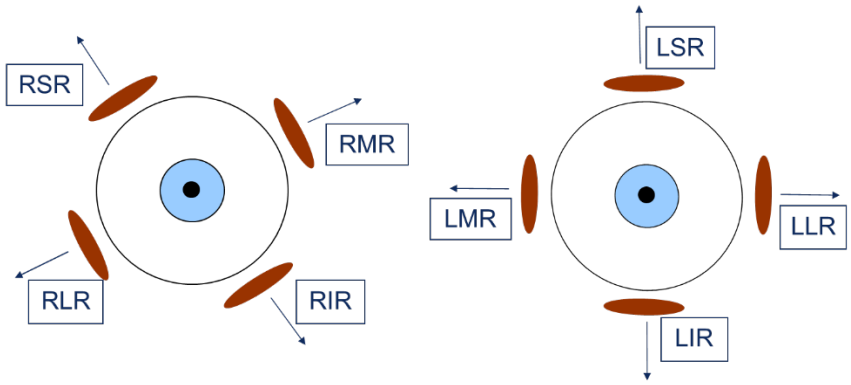

So what good is the superior oblique palsy or simulating lesion diagnosis?

- Enables intelligent referrals

- Refer unless you can prove that this strabismus is NOT the result of a recent/current sinister event (vascular, neurologic, neoplastic)
- Things that suggest it is NOT of recent sinister onset:
    - Established head tilt/turn
    - Muscle adaptations (increase comitancy)
    - Sensory adaptations (good suppression, amblyopia…)
    - Apparent/consistent orbital torsion
    - History of longstanding ET (may have had surgery)

MANAGEMENT - CONGENITAL

- Correct refractive error
- Treat amblyopia
- Surgery
    - superior oblique tuck- tendon can be lax and abnormally long
    - inferior oblique and inferior rectus weakening procedures
- Indicated when there is:
    - Strabismus
    - Marked Abnormal head position
    - Decompensation
    - Prism

MANAGEMENT - ACQUIRED

- Treat underlying cause- wait for spontaneous recovery of diplopia
- Prisms- for small angles/ Fresnel for temporary fix
- Occlusion
- Surgery
    - Ipsilateral inferior oblique recession
    - Contralateral inferior rectus recession
- Surgery for torsion
    - Harado-Ito/ Fell's procedure- superior oblique tendon placed further anteriorly and laterally

SIXTH NERVE PALSY

- Abducens nerve
- Only supplies the lateral rectus muscle
- Causes a defect of abduction

AETIOLOGY

- **Congenital**
  - Following birth trauma, forcep delivery
  - Hereditary dysgenesis
  - Maternal infection
  - Failure of lateral rectus development
- **Acquired in children**
  - Space occupying lesions
  - Infections (bacterial/viral), Middle ear infection
  - Head trauma
  - Raised intra-cranial pressure (ICP)
  - Mobius syndrome (rare disorder, 6th & 7th nerve)
  - Duane's retraction syndrome
  - Ophthalmoplegic migraine – transient migraine like headache associated with abducens neuropathy
- **Acquired in young adults**
  - Space-occupying lesions
  - Post viral inflammation
  - Multiple sclerosis
  - Diabetes
  - Ophthalmoplegic migraine
- **Acquired in older adults**
  - Vascular
  - Diabetes
  - Space occupying lesions
  - Senile lateral rectus weakness

INVESTIGATION

- History: birth trauma? Full medical history
- May complain of horizontal diplopia, notices squint (eso)
- Medical investigation
- Ophthalmic/orthoptic investigation- dd congenital esotropia & duane's retraction syndrome
- Measurement of deviation
- HESS/LEES chart

CHARACTERISTICS

Ocular posture

- Esotropia (greater at distance), check with and without abnormal head position

Abnormal head posture

- Face turn to the affected side

Muscle sequlae

- Overaction of contralateral synergist medial rectus
- Contracture of ipsilateral antagonist medial rectus
- Secondary inhibition of contralateral antagonist lateral rectus

MANAGEMENT

Adults with acquired VI nerve palsies

- Treat underlying cause – requires medical referral
- Observe for 9-12 months, can recover without treatment
- Better prognosis with vascular, traumatic and inflammatory insults compared with space occupying lesions
- Prism/occlusion to treat symptoms

Treatment after 9 – 12 months elapsed

- If condition stable: incorporation of prism if deviation is small
- Surgery
- Botox

Children with acquired VI nerve palsies

- Prevent suppression and amblyopia by use of prisms
- Surgery if required once deviation is stable and 9 – 12 months have elapsed

Children with congenital VI nerve palsies

- Treatment aimed at preventing amblyopia and preserving binocular function
- May require occlusion
- Surgery – may only be cosmetic, depending on grade of binocular vision present
- Encourage Abnormal head position for increased field of Binocular single vision

MECHANICAL STRABISMUS

- Factors within the orbit that interfere with contraction or relaxation of muscle - physical restraint on muscle
- Prevent free movement of globe

CLASSIFICATION

Congenital

- Brown's
- Duane's

Acquired

- Brown's
- Thyroid eye disease (TED)
- Orbital Injuries/ Inflammation
- Space-occupying lesions
- Retinal detachment repair

BROWN'S SYNDROME

- Absence of elevation on ADduction of the affected eye - diagnosed on excursions
- Muscle involved is Superior Oblique, also called "superior oblique tendon sheath syndrome"
    - The forced duction test (pull on superior oblique tendon with forceps) is positive, which implies a mechanical limitation somewhere in the muscle (histology suggests the limitation is in the tendon sheath)
- Without a forced duction test, Brown's Syndrome can be confused with inferior oblique underaction, so refer to ophthalmologist for differential diagnosis
- Can be unilateral or bilateral
- May be inherited condition or linked with other ocular movement disorders

- **Congenital**
    - Short superior oblique tendon sheath
    - Inelastic/short superior oblique tendon
    - Swelling or nodule on superior oblique tendon prevents free movement through the trochlea (click)
    - Anomalous innervation of superior oblique and inferior oblique
- **Acquired**
    - Injury to the trochlea (orbital injury)= scar tissue
    - Rheumatoid conditions- swelling of the tendon
    - Swelling of superior oblique

BROWNS INVESTIGATION

- Ocular motility = limitation of elevation in adduction

- History and symptoms

  - In childhood: parents report abnormal eye movements, abnormal head position, strabismus
  - In adults: pain/discomfort/tugging, clicks
- Visual acuity= amblyopia?
- Abnormal head position= chin elevation, may be head tilt to affected side (eye will be slightly hypotropic)
- Plot Hess chart- should be done quickly to avoid missing full deviations
- **Differential diagnosis**: inferior oblique underaction

MANAGEMENT - BROWNS

- Majority symptom free, Binocular single vision with small abnormal head position
- No treatment required unless abnormal head position or vertical squint
- Refractive error/ treat amblyopia
- Steroids for acquired
- Prisms
- Surgery- dip in primary position, marked abnormal head position, potential for binocular single vision

TED- THYROID EYE DISEASE

- Thyroid dysfunction- underaction (hypothyroidism) or overaction (hyperthyroidism)
- Hyperthyroidism
  - Weight loss
  - Increased appetite
  - Intolerance to heat
  - Anxiety
  - Tremor
  - Sweating
  - Increased heart rate
- Can cause a horizontal or vertical strabismus through proptosis

PHASES OF TED

- **Two phases**
- Inflammatory ‘wet’ phase- myogenic
  - Muscles are swollen in early stages, increased orbital volume caused restriction of eye movements and proptosis of the globe
- Fibrotic ‘dry’phase- mechanical
  - Fibrosis of the muscle and secondary contracture, swelling subsides (proptosis reduced) but incomitant deviation remains

SIGNS & SYMPTOMS

- Diplopia
    - typically worse in the morning (differential diagnosis: myasthenia gravis)
- Loss of vision
    - compression of optic nerve from swelling or corneal involvement (dry eye from proptosis)
- Lid retraction and lid lag
- Proptosis
- Oedema
    - corneal opacities/ chemosis
- Cover test
    - hypotropia present, esotropia
- Ocular movements
    - muscles dry up and harden, limitation in opposite direction of muscle movement
- Order of frequency of muscles affected
    - Inferior rectus- limits up gaze
    - Medial rectus- limits abduction
    - Superior rectus- limits down gaze
- Abnormal head position- usually chin elevation to reduce limitation in up gaze

INVESTIGATION

- History – nature & duration of symptoms
- Visual acuity
- Eyelid position and function, globe position
- Cornea
- Fundus/optic disc
- Colour vision- red/green defects
- Peripheral vision
- Orthoptic: versions and ductions (will determine whether mechanical)
- Repeated measurements to record change

MANAGEMENT

- Medical
    - Drugs to reduce/increase thyroid function
    - Removal of thyroid gland (hyper)
    - Radiotherapy of thyroid gland

- Ocular
    - Surgical decompression of orbit
    - Keep patient comfortable- prisms, lubricants
    - Surgery once condition is stable- overcome symptoms & increase binocular field of view

DUANE'S SYNDROME

- Also called Duane's Retraction Syndrome (DRS)
- Congenital condition, can be bilateral or unilateral
- Relatively common
- Aetiology- not fully known, innervational or mechanical
    - Innervational
    - Miswiring of 3rd and 6th nerves
    - Innervation of the lateral rectus by extra branches of 3rd nerve
    - 6th nerve absent or partially formed
    - Disruption of development in embryo
    - Often associated with other congenital defects e.g. coloboma, cataracts, cleft lip
    - Innervates adduction and abduction at the same time

MECHANICAL AETIOLOGY

- Can also be caused by thin, elastic muscles
- Muscles bound to orbital wall
- Incorrect insertion of medial recti/ tight medial rectus
- Inelastic, fibrotic lateral rectus with abnormal insertions

CLASSIFICATION

- **Brown (1950)**
    - A – limitation of abduction, less limitation of adduction
    - B – limited abduction, normal adduction
    - C – limitation of adduction exceeds limitation of abduction
- **Huber (1974)**
    - Type I – limitation of abduction (lateral rectus no innervation), less limitation to adduction (lateral rectus some innervation)
    - Type II –limited adduction, lateral rectus has innervation on abduction and adduction, therefore can abduct and also counteracts medial rectus limiting adduction
    - Type III – limited abduction and adduction, lateral rectus no innervation to abduct but is innervated on adduction and counteracts medial rectus

CHARACTERISTICS OF DUANE'S SYNDROME

- Limitation of abduction
- Less limitation of adduction in same eye
- Globe retraction on adduction with narrowing of palpebral fissure
- Widening of palpebral fissure on abduction
- Poor convergence
- Face turn to affected side
- Upshoot or downshoot of affected eye on adduction

DUANE'S SYNDROME INVESTIGATION

- History: abnormal eye movement, abnormal head position, strabismus
- Visual acuity: amblyopia if manifest strabismus in Primary Position
- Abnormal head position- face turn to affected side
- Cover test- w & w/o Abnormal head position
    - Typically convergent deviation
- Ocular movements- abduction and adduction/ upshoots & downshoots
    - Retraction of globe and closure of Palpebral Fissure
- Convergence-poor Binocular Function
- Binocular single vision- good, maintained by head position
- Hess
- Differential diagnosis- 6th nerve palsy, medial wall fracture, inflammation
- Associated signs

DUANE'S SYNDROMEMANAGEMENT

- Often no treatment required, asymptomatic with Abnormal head position and head movements
- Refractive error / Amblyopia
- Indications for treatment
    - Decompensation
    - Abnormal head position and strabismus cosmesis
- Aims
    - Place field of Binocular single vision centrally
    - Reduce Abnormal head position
    - Improve cosmesis
- Surgery/ Botox

ORBITAL TRAUMA

- Blow-out fracture
- Soft tissue injury- no fracture of bone, muscle damage, laceration
- Supra-orbital fracture- sharp objects going through orbital roof
- Naso-orbital fracture- direct trauma to naso-orbital region, road traffic accidents
- Zygoma fracture- cheekbone, traumatic enophthalmus or proptosis

BLOW-OUT FRACTURE

- Blunt trauma
- Object with larger diameter than orbit
- Pressure pushes contents of globe backwards
- Rise in pressure fractures wall- most commonly medial and orbital floor
    - Pure: trap door common (fist, cricket ball, knee)
    - Impure: orbital rim also involved (Road traffic accidents)

MECHANISM

- Limitation of ocular movements due to entrapment of muscle or muscle pulleys/sheaths etc. from fractured bone
- May be muscle restriction due to inflammation of injured muscles
- Movement is restricted rather than palsied
- Most often traps (& restricts) the inferior rectus muscle

BLOW-OUT INVESTIGATION

- History and general observation - periorbital ecchymosis, diplopia, pain!
- Visual acuity- reduced where hypaema or perforation of globe, trauma to optic nerve
- Abnormal head position- chin elevation for orbital floor, face turn if medial wall
- cover test: enophthalmus, hypotropia (dependent on where fractured)
- ocular movements- typically limited elevation and depression (orbital floor), limited ab/adduction with medial wall
- Diplopia- may swap direction depending on direction of gaze
- Hess- gross limitations on outer fields, limitation on opposite directions, typically vertical
- Examine fundus and media, globe damage from impact
- X-ray of orbit
- Intra-ocular pressure (IOP)- in different positions of gaze, greatest in position of greatest limitation
- Forced duction test- neuro/mechanical

MANAGEMENT

- Recovery should be allowed approx. 14 days
- Prisms
- Indications for surgery- to repair orbital floor & release trapped muscle, prevent fibrosis, correct strabismus
    - diplopia
    - enophthalmos
    - large fractures
    - globe retraction
    - increase in IOP on upgaze
- Late referrals do not respond as well to treatment/ formation of bony callus prevents freeing of muscle

MYOGENIC STRABISMUS

- Weakness of ocular movement is due to a primary problem affecting the muscle itself
- Can involve individual extra ocular muscles or a combination of muscles
- Often bilateral condition

- Classification
    - Chronic Progressive External Ophthalmoplegia (CPEO)
    - Myasthenia Gravis (myasthenia gravis)
    - TED (myogenic & mechanical)
    - Lambert-Eaton-Rooke syndrome (LERS)
    - Ocular Myositis

CHRONIC PROGRESSIVE EXTERNAL OPHTHALMOPLEGIA (CPEO)

- Rare muscle dystrophy
- Progressive symmetrical loss of ocular motility usually accompanied by ptosis and orbicularis weakness
- Smooth muscle usually not affected- pupil constriction spared and accommodation
- Usually diagnosed <30 years old, hereditary
- Often progresses to complete ophthalmoplegia
- Unlikely to have remissions
- Diplopia may be presenting symptom depending on symmetry

AETIOLOGY

- Primary myopathy of the extraocular muscles
- Associated with mitochondrial disease

- Isolated condition or part of a more widespread disorder
    - Kearns-Sayre-Daroff syndrome
        - CPEO in childhood
        - Fine pigmentray retinopathy
        - Heart conduction block

PRESENTING SIGNS

- Ptosis: lids droop to the point of the visual axis
- Head tilt backwards to try to lift lids
- Raised forehead/brow to lift lids
- More likely to move head due to lack of eye movement
- Exposure keratopathy – due to weakness of orbicularis

MANAGEMENT

- Diagnosis- muscle biopsy, irregular mitochondria
- Ptosis props
- Prisms for diplopia if occurs
- Surgery for ptosis, need to be careful of exposure keratopathy
- May have large exotropia, surgery to re-align, often reoccurs

MYASTHENIA GRAVIS

AETIOLOGY

- Genetic, auto-immune disease
- Motor impulses from brain not transmitted effectively by neuro-muscular junctions, causing progressive muscle weakness (any muscle)
- Relatively rare: 1 in 10,000
- Between age of 20-40, women more at risk
- Has ocular and non-ocular features
- Present with ptosis, diplopia or both (extraocular muscles affected first)
- Remissions can occur

MYASTHENIA GRAVIS – FEATURES

- Diurnal variation- worse at the end of the day
- Order of frequency of affected muscles
    - extraocular muscles, facial, bulbar, neck, limb girdle, distal limb and trunk muscle

- Extraocular muscles affected in all types of myasthenia, if only extraocular muscles for 2 years, unlikely to progress to rest of muscles
- If respiratory muscles are affected the illness can prove fatal
- Associated with diabetes, TED, rheumatoid arthritis

SYMPTOMS AND SIGNS

- Ptosis
- Diplopia
- Limitation of ocular movement –can mimic any nerve palsy. Vertical muscles> horizontal (inferior rectus)
- Orbicularis weakness
- Limb girdle weakness
    - Problems rising from seat, climbing stairs, holding arms above head from any length of time
- Bulbar and respiratory muscle weakness

CLASSIFICATION

- Paediatric
    - Neonatal
    - Congenital
    - Juvenile
- Adult
    - Ocular
    - Generalised
        - Mild to moderate
        - Acute fulminating
        - Late severe

INVESTIGATION

- Case history
- ocular movements - variability
- Simpson test
- Cogan's lid twitch
- Hess chart
- Tensilon test- Anticholinesterase injected intravenously, improves muscle function within one minute
- Antibodies measured in blood serum
- Radiology- assessment of the thymus

MANAGEMENT

- Anticholinesterase drugs/ steroids
- Thymectomy
- Prisms / Occlusion
- Ptosis props
- Surgery- contraindicated until stabilised

LERS- LAMBERT EATON ROOKE SYNDROME

- Transmission defect is presynaptic rather than post as in myasthenia gravis
- Strongly linked to carcinoma of the lung
- Extraocular muscles involvement is rare, lack of movement of the legs
- Limb girdle weakness
- Dry mouth
- Ptosis

OCULAR MYOSITIS

- Rare idiopathic inflammatory disorder affecting the extraocular muscles
- Present in the absence of thyroid disease, myasthenia gravis or other autoimmune disorders

- Unilateral or bilateral, can be affecting one or many extraocular muscles
- Presents with painful diplopia, few other signs
- Function impaired
    - Lid swelling, chemosis, proptosis, ptosis

OCULAR MYOSITIS - MANAGEMENT

- Steroids
- Surgery
    - Residual restrictive strabismus

ALBINISM

BACKGROUND

- Albinism is a generalized or localized hypopigmentation disorder affecting hair, skin and/or eyes, and is of genetic origin

SYMPTOMS

- Lack of pigment
- Ocular albinism commonly causes nystagmus, most commonly periodic alternating nystagmus (PAN)

ASSESSMENT

- Observe pigmentation, VA is generally reduced to about 6/24, look for nystagmus
- Stereoacuity is usually reduced, fusion poor, and strabismus common

MANAGEMENT

- Albinism is associated with Chediak-Higashi (WBC) syndrome and Hermansky Pudlak (platelet) disorder – so ask a medical practitioner to consider these
- Management of nystagmus as per “Strabismus and Nystagmus” section. Additionally consider glare protection

RETINAL DISORDERS (NEEDING MEDICAL ASSESSMENT)

- An intra-orbital mass (tumour or other lesion displaces extraocular muscles) can produce an incomitant strabismus NOT characteristic of any cranial nerve disorder

RETINOBLASTOMA

BACKGROUND

- Prevalence is fairly stable worldwide at approximately 1 in 15,000 infants
- Malignant tumour of the photoreceptor layer
- Can be unilateral or bilateral
- Prognosis is directly related to the size and extension of the tumour
  - So refer IMMEDIATELY

SYMPTOMS

- Most common presentation is leukocoria (often but not always in history); strabismus is also common

ASSESSMENT

- MUST be competent at Brückner's test
- MUST always assess posterior pole
- MUST do dilated fundus examination (DFE) on indication

MANAGEMENT

- MUST refer immediately if identified or even if unsure
- Specialist treatment is via irradiation and/or enucleation

Leukocoria caused by retinoblastoma (Source: Merck Manual Professional Edition online)

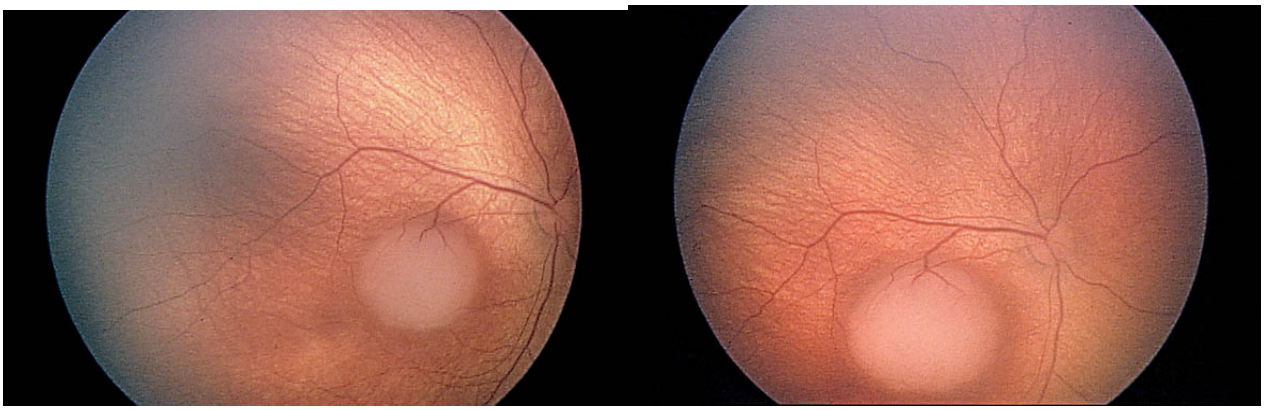

Figure 15.1: Retinoblastoma in an infant – left image taken on a Friday, right image (same eye) taken on Monday when returning for treatment. NB – these can progress rapidly, refer to best care immediately.

CHORIORETINAL DEGENERATIONS

BACKGROUND

- Coat's disease involves lipid leakage into retina from abnormal retinal blood vessels. The cause of Coat's disease is unknown – the genetics are not understood. The most common onset is in 8 year old boys
- Retinal detachment
- Toxocara and toxoplasmosis infections

SYMPTOMS

- Coat's disease commonly presents with leukocoria or strabismus
- Retinal detachment may present after blunt eye or head trauma, sometimes with photopsia, metamorphopsia, floaters, etc
- Active toxo infections can present with generalized inflammation; inactive toxo scars can present with vision loss (mostly only if large or involving macular); either can be asymptomatic

ASSESSMENT

- Ocular fundus examination, preferably through dilated pupils, is the critical assessment
- Search for predisposing factors for retinal detachment (e.g. high myopia, peripheral degenerations/tears/holes)
- OCT, slit lamp (e.g. to look for accompanying anterior uveitis), VA and visual fields can all be useful

MANAGEMENT

- Refer for management, preferably to a retinal specialist, urgently if there is active disease

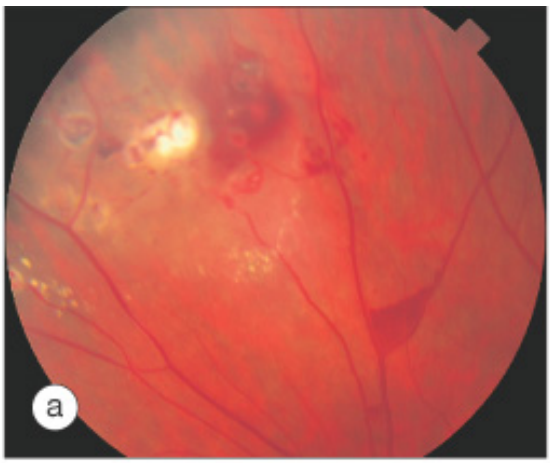

© 2005 Elsevier Ltd. Pediatric Ophthalmology and Strabismus 3e.

Figure 15.2: Left image: Coat's disease (courtesy of Taylor and Hoyt 2005).

Right image: inactive toxoplasmosis scar (courtesy Tim Fricke and ACO)

SUMMARY OF DIAGNOSIS OF STRABISMUS DISORDERS

- Other causes of strabismus include diabetic retinopathy and retinal detachment
- **Thorough differential diagnosis of strab MUST include comprehensive assessment of the posterior segment, either by you or by an ophthalmologist**
- You must be able to answer the following question for all pts with strab:
    - WHY DOES THIS PATIENT HAVE THIS STRABISMUS AT THIS TIME?
        - Recent onset strab can be a medical emergency, never start treatment or discharge a patient without finding the cause
        - Either find the cause yourself, or refer for a diagnostic opinion
        - Always remember where you are in your examination

REHABILITATION OPTIONS FOR INCOMITANT STRABISMUS

- In addition to requiring an aetiological diagnosis, incomitant strabismus often also demands rehabilitative care
    - To alleviate diplopia
    - To achieve comfortable head posture
    - To improve cosmesis
- Options include prisms, patching, penalisation, surgery
    - Recent onset palsies are highly incomitant and vary over time
    - A patch can neutralise disabling diplopia
    - This can delay or avoid more expensive treatments (some incomitant strabismus will self-resolve)
    - Consider optical and/or translucent penalisation, but more often you'll need an opaque patch
    - Prism
        - Consider prescribing the primary gaze deviation to allow correct head posture
        - Consider prescribing yoke prisms to move eyes towards position of decreased torsion
    - Surgery for incomitant strabismus is a highly specialised field - assist your patients to find an appropriate strabismologist

MICROTROPIA

CHARACTERISTICS

- Unilateral manifest strabismus <10 dioptres
- Foveal suppression scotoma of affected eye
- Abnormal Binocular single vision
- Reduced visual acuity in deviating eye – 6/9?

- Anisometropia common
- Parafoveolar fixation/ abnormal retinal correspondence
- Reduced Stereopsis

CLASSIFICATION

- Primary Microtropia
    - With identity
        - No manifest deviation seen
    - Without identity
        - Manifest deviation noted on cover test
- Secondary (consecutive) Microtropia
    - Following optical or surgical correction for a larger manifest deviation

AETIOLOGY AND INVESTIGATION

- Anisometropia- defocused image in the more ametropic eye
    - Foveal suppression scotoma
- Aim is to diagnose microtropia and assess quality of binocular single vision from fusional amplitude and stereoacuity
- Visual acuity- generally 1 line worse than better eye
- Cover test-small manifest strabismus (flick) in without identity
    - Latent deviation, check speed of recovery to assess compensation
- Fixation- eccentric? Nasal and superior in esot
- 4 prism dioptre test base out- checking for central suppression scotoma
- Bagolini lenses, Worth Four Dot
- Fusion amplitude- can indicate compensation of any latent deviation
- Stereotests
- Measurement- prism cover test- place prism in front of microtropic eye, cover/uncover on normal eye until neutral

MANAGEMENT

- Correct refractive error, constant wear
- Obtain and maintain best visual acuity- part-time occlusion
- Restore good binocular single vision
- Can be associated with fully accommodative esotropia